

Mastopexy Revisited: A Review of 150 Consecutive Cases for Complication and Revision Rates

W. Grant Stevens, MD; David A. Stoker, MD; Mark E. Freeman, MD; Suzanne M. Quardt, MD; and Elliot M. Hirsch

Drs. Stevens, Stoker, Quardt, and Mr. Hirsch are from Marina Del Ray, CA. Dr. Freeman is in private practice in Jacksonville, FL.

Background: Although there is an abundance of data in the literature regarding the safety of breast reduction and augmentation, nearly all of the literature concerning mastopexy describes techniques. There are few studies regarding revision and complication rates for mastopexy procedures.

Methods: A retrospective review was performed on a series of 150 consecutive patients who underwent a mastopexy procedure. Operations were performed by one of two surgeons (W.G.S. or D.A.S.) in an outpatient surgery center over a 6-year period (1999–2005), with an average follow-up of 36 months. Patients were identified as being either primary (no previous breast surgery) or secondary (history of at least one previous breast surgery). The type of mastopexy design was recorded (inverted-T or vertical), and trends were examined. Complication and revision rates were observed, and their rates were calculated.

Results: One hundred forty-eight women underwent bilateral and two underwent unilateral mastopexy for a total of 150 women and 298 breasts. There were 119 primary and 31 secondary patients. Mastopexy incision designs were as follows: 86% inverted-T and 14% vertical. There were no major complications. The most common complications were poor scarring (6%) and seroma formation (2.7%). The revision rate was 8.6%; 75% of revisions were for poor scarring. Some of these were performed with the patients under local anesthesia or at the time of a subsequent unrelated surgery.

Conclusions: Our series of 150 consecutive patients, with no major complications and a revision rate of 8.6% over an average of 36 months, indicates that mastopexy may be considered a safe and effective procedure. (Aesthetic Surg J 2007;27:150–154.)

“P¹ptosis” is derived from the Greek word “fall,” and is defined as the “abnormal lowering or prolapse of an organ or body part.”¹ Ptosis of the breast is an increasingly frequent concern for many patients, because the media portrays women of all ages as having youthfully shaped breasts. While a significant number of women never have an elevated nipple-areolar complex, the effects of time and childrearing eventually result in descended breasts in most women. The degrees of ptosis have previously been categorized by Regnault.²

Mastopexy is a commonly performed procedure that is becoming increasingly popular. Since 1997, the number of breast lift procedures has risen 509%, which is a larger percent increase than any surgical procedure other than brachioplasty.³

The development of modern mastopexy techniques has occurred concurrently with innovations in breast reduction surgery. In 1907, Morestin⁴ was the first to describe the transposition of the nipple areola complex to a new

position. In the 1930s, Schwarzmann⁵ described the process of deepithelialization of the tissue surrounding the nipple-areolar complex to preserve the vascular plexus. Wise⁶ developed his pattern in the 1950s, which has become the standard for preoperative geometric marking. Since then, numerous advancements have been advocated, including the use of Marlex mesh to support the breast, circumareolar mastopexy, the vertical approach,⁷⁻¹² and slips of pectoralis muscle to support the breast.

Although techniques concerning mastopexy patterns have been published,¹³⁻¹⁶ few studies document the common complication and revision rates. In this study, we review the complications and revisions of 150 consecutive mastopexy cases in patients with significant breast ptosis.

Methods

A retrospective chart review was performed of 150 consecutive mastopexy procedures performed at a single outpatient facility by one of two surgeons (W.G.S. or

D.A.S.) over a 6-year period (1999–2005). Average patient follow-up was 36 months.

All patients included in this study had breast ptosis classified as Regnault II or higher on physical examination. The type of mastopexy (inverted-T versus vertical), history of previous breast surgery, and any concomitant procedures were recorded. Postoperative data, including complications, treatment of complications, revisions, reasons for revision, and patient or surgeon dissatisfaction were analyzed retrospectively.

Preoperative photos were taken, and all patients were marked while standing. All patients received general anesthetic, lower extremity sequential compression devices (placed before induction), and perioperative antimicrobial coverage. Extensive undermining of mastopexy flaps was avoided when possible, and no drains or Foley catheters were used. After surgery, patients were generally transferred to an after-care facility, intermittently ambulated, and maintained on oral pain medication. When comparing complication and revision rates between procedures, statistical significance was determined with χ^2 analysis.

Results

The senior author (W.G.S.) was the primary surgeon for 98 patients (65.3%). One hundred forty-eight patients underwent bilateral mastopexy, whereas 2 patients had a unilateral procedure, for a total of 298 breast procedures. Thirty-one of the 150 patients (20.6%) had undergone previous breast surgery, with the most common procedure being previous placement of breast implants (8.6%). Seventy-five patients (50%) had at least one other concurrent surgical procedure at the time of the mastopexy, with the most common being lipoplasty (53% of concurrent procedures). The traditional Wise (or inverted-T) pattern was performed in 130 patients (86.6%), whereas a vertical mastopexy with no horizontal component was completed in 20 (13.3%).

No severe complications (death, myocardial infarction, pulmonary embolus, deep venous thrombosis) occurred in any of the patients over the mean follow-up period of 36 months. There were no cases of partial or complete flap or nipple loss. In one patient (0.7%) temporary radial nerve palsy developed because of positioning, which was resolved with conservative management. The most common complications were poor scarring (6%) and seroma formation (2.7%). The distribution of complications is summarized in Table 2.

Thirteen patients (8.6%) required some form of revision surgery within the follow-up period. Eight of the

150 patients (5.3%) required a return to the operating room, whereas 5 revisions (3.3%) were performed in the office with the patient under local anesthesia. All office procedures were for either poor scarring or a lateral “dog ear.” Interestingly, 75% of the revision procedures were for scar-related issues (Table 3).

The overall complication and revision rates for the patients undergoing Wise (or inverted-T) pattern mastopexy were compared to those for patients undergoing vertical mastopexy. The difference in complication and revision rates between the two groups of patients was not statistically significant ($P < .05$). No statistically significant difference with respect to complication and

Table 1. Regnault classification

Classification	Ptosis	Description
Grade I	Minor	Nipple at the inframammary fold
Grade II	Moderate	Nipple below the inframammary fold but above lower breast contour
Grade III	Severe	Nipple at lower breast contour

Table 2. Complication rates

Complications	No. (%)
Poor scarring	9 (6)
Seroma	4 (2.7)
Hematoma	3 (2)
“Dog ear” formation	3 (2)
Minor infections	2 (1.3)
Radial nerve weakness	1 (0.7)
Persistent ptosis	1 (0.7)
Asymmetry	1 (0.7)

Table 3. Revision rates

Indications for revision in operating room	No. (%)
Poor scarring	6 (4)
Recurrent/persistent ptosis	1 (0.7)
Asymmetry	1 (0.7)

revision rates was found between primary patients and those with previous breast surgery.

Discussion

Although countless plastic surgeons have performed the traditional Wise pattern mastopexy over the last 50 years, few studies in the literature discuss actual complication and revision rates. This review of mastopexy procedures for safety and efficacy fills an important gap in the medical literature.

When one thinks of potential complications caused by mastopexy, nipple or flap necrosis are among the most devastating. It is interesting to note that although flap undermining was minimized where possible, partial flap

or nipple loss was not experienced. Although no severe complications were noted, the number of patients with poor scarring (6%) was significant. Of patients requiring some form of revision, 75% of revisions were the result of a poor scar. Only two patients (1.3%) required a revision for the overall shape of the breast itself.

The efficacy of a surgical procedure that addresses breast ptosis may be determined by the calculation of revision rates, as well as the objective analysis of the final results and patient satisfaction. We have included recent digital photos of patients with significant ptosis as representative samples of our surgical results (Figures 1 and 2). Although not included in this study,

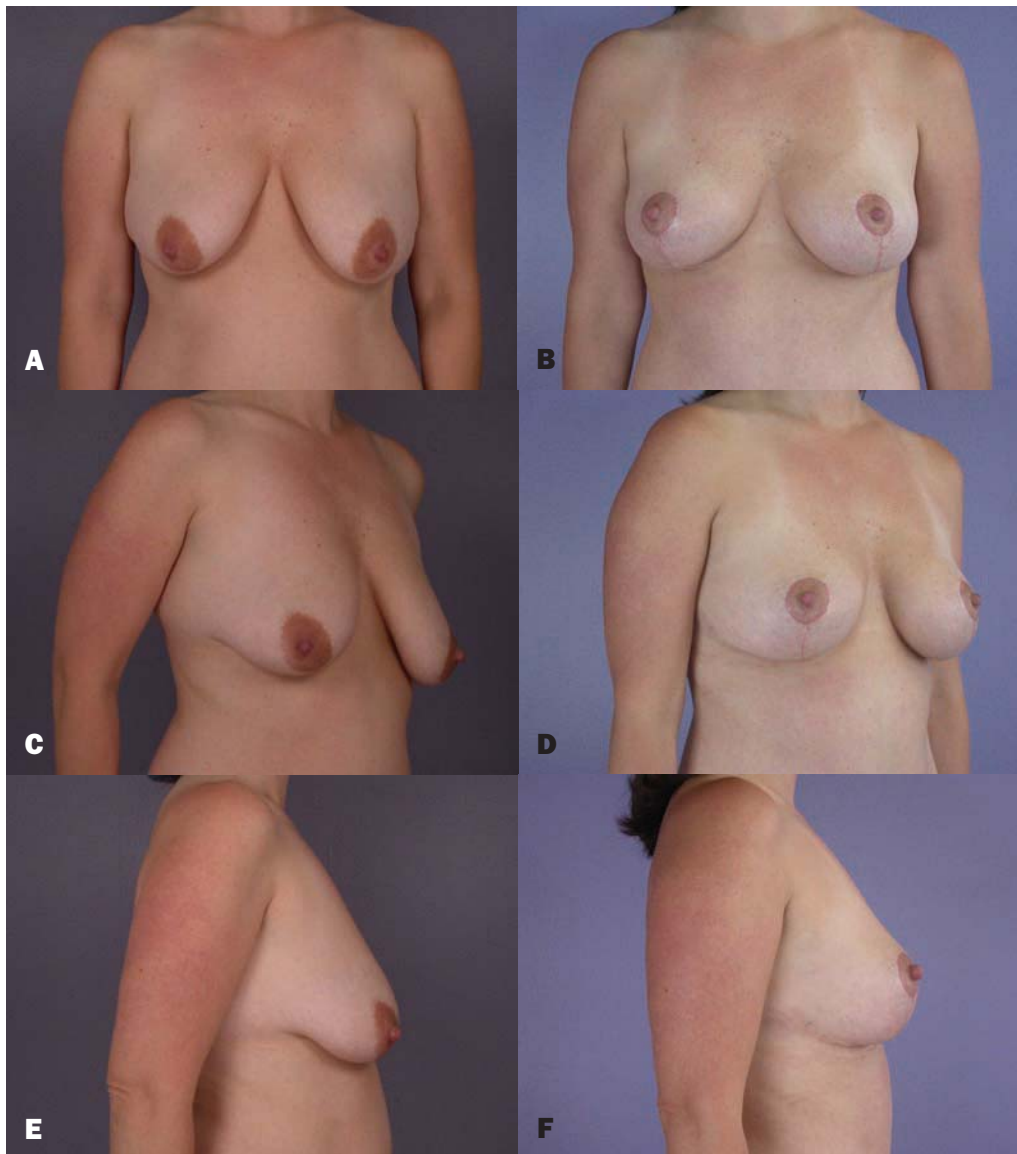


Figure 1. A, C, E, Preoperative photographs of a 38-year-old woman. B, D, F, Postoperative photographs 5 weeks after bilateral mastopexy with inverted-T incision.

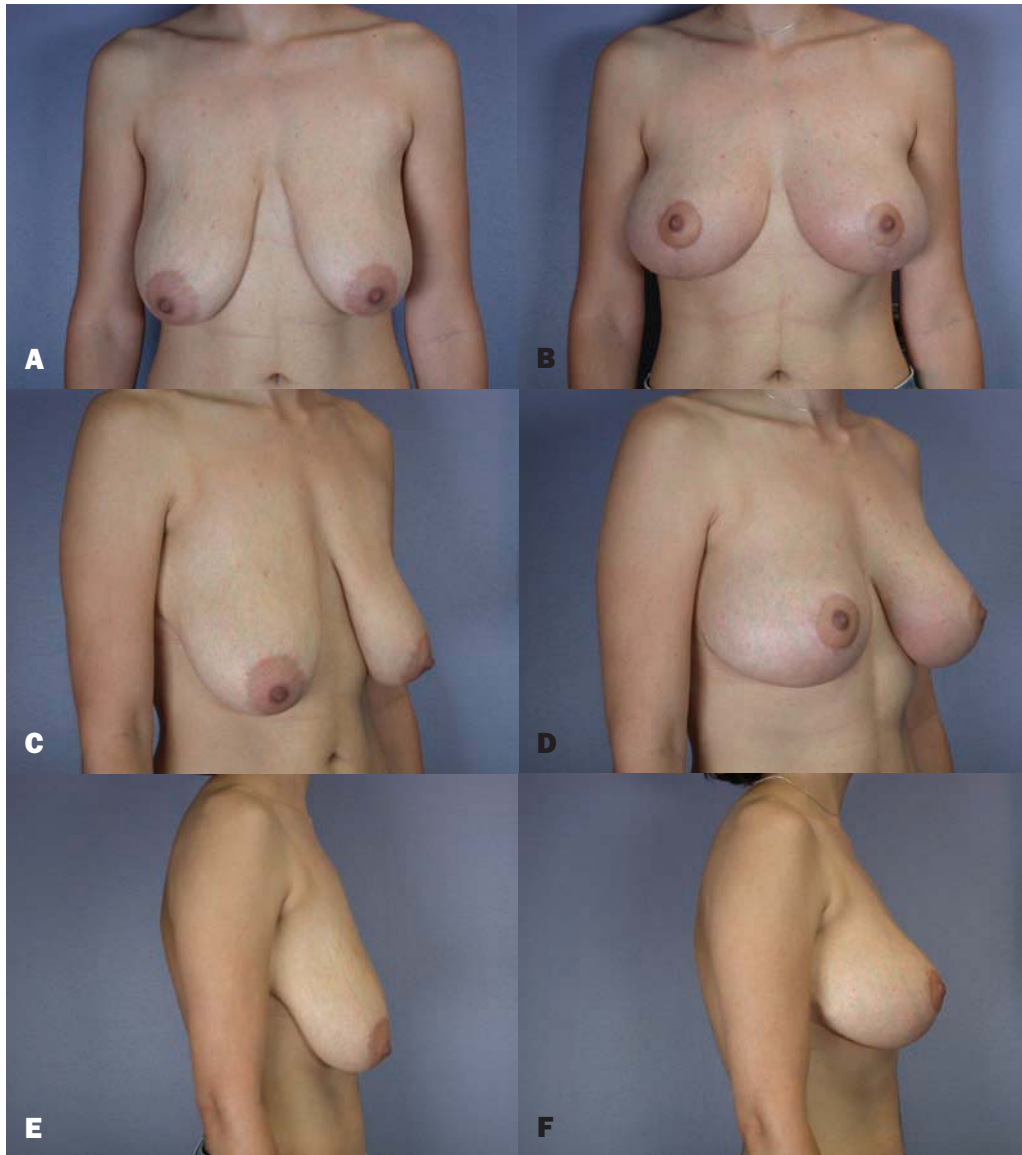


Figure 2. A, C, E, Preoperative photographs of a 25-year-old woman. **B, D, F,** Postoperative photographs 3 months after bilateral mastopexy with inverted-T incision.

patient satisfaction questionnaires would likely be an interesting addition to the study of our own results in the future.

Although the use of vertical scar mastopexy procedures is increasing, our primary choice remains the Wise (or inverted-T) pattern mastopexy, especially for larger breasts and greater degrees of ptosis. There was no statistically significant difference in the complication or revision rates between procedures performed with the inverted-T technique versus the vertical technique.

Conclusion

Mastopexy is currently a common procedure, and the number of mastopexy surgeries performed nationally has increased dramatically over the past decade.³ Although numerous studies have described original techniques, few studies have focused on complication and revision rates. Our study demonstrates mastopexy is both a safe and effective procedure, with no major complications and a revision rate of 8.6% in our series of patients. ■

References

1. *The American Heritage Dictionary of the English Language*. Fourth ed. Boston: Houghton Mifflin; 2000.
2. Regnault B. Breast ptosis: definition and treatment. *Clin Plast Surg* 1976;3:193-203.
3. American Society for Aesthetic Plastic Surgery: 2005 Cosmetic Surgery National Data Bank. New York: American Society for Aesthetic Plastic Surgery; 2005.
4. Morestin H. Bilateral mammary hypertrophy corrected by discoid resection. *Bull Mem Soc Chir Paris* 1907;33:201.
5. Schwarzmann E. Avoidance of nipple necrosis by preservation of corium in one-stage plastic surgery of the breast. *Rev Chir Struct* 1937;10:206-209.
6. Wise RJ. A preliminary report on a method of planning the mammoplasty. *Plast Reconstr Surg* 1956;17:367-395.
7. Johnson GW. Central core reduction mammoplasties and Marlex suspension of breast tissue. *Aesthetic Plast Surg* 1981;5:77-84.
8. Benelli L. A new periareolar mammoplasty: the "round block" technique. *Aesthetic Plast Surg* 1990;14:93-100.
9. Lejour M. Vertical mammoplasty and liposuction of the breast. *Plast Reconstr Surg* 1994;94:100-104.
10. Hall-Findlay EJ. A simplified vertical reduction mammoplasty: shortening the learning curve. *Plast Reconstr Surg* 1999;104:748-763.
11. Lassus C. Breast reduction: evolution of a technique-A single vertical scar. *Aesthetic Plast Surg* 1987;11:107-112.
12. Graf R, Biggs TM. In search of better shape in mastopexy and reduction mammoplasty. *Plast Reconstr Surg* 2002;110:309-314.
13. Lockwood T. Reduction mammoplasty and mastopexy with superficial fascial system suspension. *Plast Reconstr Surg* 1999;103:1411-1420.
14. Erol O, Spira M. Mastopexy technique for mild to moderate ptosis. *Plast Reconstr Surg* 1980;65:603-609.
15. Hammond D. Short scar periareolar inferior pedicle reduction (SPAIR) mammoplasty. *Plast Reconstr Surg* 1999;103:890-902.
16. Marchac D, de Olarte G. Reduction mammoplasty and correction of ptosis with a short inframammary scar. *Plast Reconstr Surg* 1982;69:45-55.

Accepted for publication September 28, 2006.

Reprint requests: W. Grant Stevens, MD, 4644 Lincoln Boulevard, Suite 552, Marina del Rey, CA 90292.

Copyright © 2007 by The American Society for Aesthetic Plastic Surgery, Inc.

1090-820X/\$32.00

doi:10.1016/j.asj.2006.12.014