

# Does Lipoplasty Really Add Morbidity to Abdominoplasty? Revisiting the Controversy With a Series of 406 Cases

**W. Grant Stevens, MD; Robert Cohen, MD; Steven D. Vath, MD; David A. Stoker, MD; and Elliot M. Hirsch**

Dr. Stevens and Dr. Stoker are in private practice in Marina del Rey, CA. Dr. Cohen is in private practice in Scottsdale, AZ. Dr. Vath is in private practice in Denver, CO. Mr. Hirsch is at the Keck School of Medicine, University of Southern California, Los Angeles, CA.

**Background:** The popularity of plastic surgery “makeover” television programs has increased interest among the public and the medical community in both the positive and negative aspects of combined surgery procedures. In particular, the safety of combining abdominoplasty with lipoplasty became a matter of concern following multiple deaths in Florida and the consequent moratorium on simultaneous abdominoplasty and lipoplasty enacted by the Florida Board of Medicine.

**Objective:** The goal of this study was to evaluate the morbidity of abdominoplasty combined with suction-assisted lipoplasty (SAL) compared to the morbidity of abdominoplasty alone.

**Methods:** A retrospective review of 406 consecutive abdominoplasty procedures performed by the senior author (W.G.S.) at a single outpatient surgery center was conducted. Cases were sorted into 2 groups: those that had abdominoplasty only and those that had abdominoplasty with SAL. The SAL group was further subdivided into 4 groups based on the volumes of aspirate removed. The primary groups and subgroups were compared with regard to morbidity. In addition, the location of SAL, age, body mass index (BMI) and surgery time of each patient were evaluated as contributing factors to morbidity.

**Results:** No statistically significant differences in complication rates were found when comparing abdominoplasty with SAL to abdominoplasty alone. Additionally, the amount and location of lipoplasty, age, BMI and surgery times did not significantly affect patient morbidity. The prevalence of morbidity in all groups compared favorably to parameters established in previous studies of abdominoplasty and SAL.

**Conclusions:** This extensive retrospective study provides further evidence that combining abdominoplasty with SAL does not increase patient morbidity compared to abdominoplasty alone. (*Aesthetic Surg J* 2005;25:353-358.)

Although the practice of performing multiple aesthetic procedures in a single session is not new, awareness of both the positive and negative aspects of this type of surgery has been heightened recently. Fueled by plastic surgery “makeover” television programs, there has been an increased demand by patients to have multiple cosmetic procedures during one trip to the operating room. This reflects a desire to minimize cost and time out of work, while maximizing the immediate aesthetic impact of surgery.

As the public call for multiple simultaneous procedures increases, however, so do the concerns for potential complications as a result of these combined procedures. On February 11, 2004, the Florida Board of Medicine instituted a temporary moratorium on abdominoplasty combined with suction-assisted lipoplasty (SAL) in the office setting, mandating a minimum 14-day interval between

these two procedures.<sup>1</sup> This action was taken in response to 8 office-surgery deaths in Florida, including 3 that involved abdominoplasty combined with lipoplasty. The decision by the Florida Board of Medicine reflected the common belief that combination procedures are inherently dangerous.

Multiple studies have addressed the issue of combining abdominoplasty with other surgical procedures.<sup>2-7</sup> In a recent article, Stevens et al<sup>8</sup> evaluated 248 abdominoplasty patients in an effort to evaluate whether combining multiple cosmetic surgery procedures increased the incidence of major or minor complications. In this retrospective study, it was noted that no statistically significant difference in complications occurred between patients undergoing abdominoplasty alone, and those having abdominoplasty combined with facial and/or breast surgery.

**Table 1. Lipoplasty groups**

Group	Lipoplasty	No. cases
Group 1	No lipoplasty	57
Group 2A	Lipoplasty with <1000 mL aspirate	100
Group 2B	Lipoplasty with 1000-3000 mL aspirate	171
Group 2C	Lipoplasty with >3000 mL aspirate	39
Group 2D	Lipoplasty with unquantified aspirate	39

In the process of gathering and analyzing data for this combined surgery study, a large subgroup of abdominoplasty patients was identified that had undergone simultaneous SAL. The current study was created specifically to evaluate and compare the complication rate among patients having abdominoplasty without lipoplasty to those having abdominoplasty with lipoplasty, and will hopefully shed further light on the safety of combining abdominoplasty with lipoplasty. This paper also represents a larger patient series and a longer follow-up period as compared to our previous study.

## Methods

The data collected represent a retrospective chart review of 406 consecutive abdominoplasty procedures performed at a single outpatient facility by the senior surgeon (W.G.S.) over a 15-year period (1989-2004). Four patients had a repeat abdominoplasty after postoperative weight gain, making the total number of patients 402. Abdominoplasty procedures performed by the senior author at other facilities were excluded from this study.

Two groups of patients were compared: those who underwent abdominoplasty without SAL and those who had abdominoplasty with SAL. Many patients also had simultaneous aesthetic facial and/or breast procedures. As demonstrated by the senior author's prior study,<sup>8</sup> these additional procedures were not associated with a higher complication rate when combined with abdominoplasty.

Minor complications assessed included seromas, hematomas, infections, and small (<5 cm) wound breakdowns. Major complications evaluated included large (>5 cm) flap necrosis, need for blood transfusion, deep vein thrombosis, pulmonary embolus, myocardial infarction, and death. Additional data compiled included age, gender, tobacco use, body mass index (BMI), past medical history, American Society of Anesthesiologists (ASA) physical status level,<sup>9</sup> and operative times. The location

and amount of lipoplasty aspirate from each patient were recorded during the review.

Hypertrophic or aesthetically suboptimal scar formation was not specifically included as a complication in this study. Although surgical technique affects the quality of the final scar, genetic predisposition towards hypertrophic scarring can represent a significant factor in healing as well. Complications such as dehiscence or infection may result in a hypertrophic scar, and in these instances, the morbidity was defined by the inciting complication rather than the scar itself.

All patients received general anesthesia, lower-extremity sequential compression devices (placed prior to induction), and perioperative antimicrobial coverage. When adjunctive lipoplasty was performed, aggressive treatment of the lower abdomen was avoided to minimize interference with the blood supply to the distal flap.<sup>10</sup> Closed suction drains were placed in all patients. No indwelling Foley catheters were used, and all patients ambulated within 1 hour of awaking from anesthesia. Patients were generally transferred to an aftercare facility, ambulated intermittently, and maintained on oral pain medication.

## Results

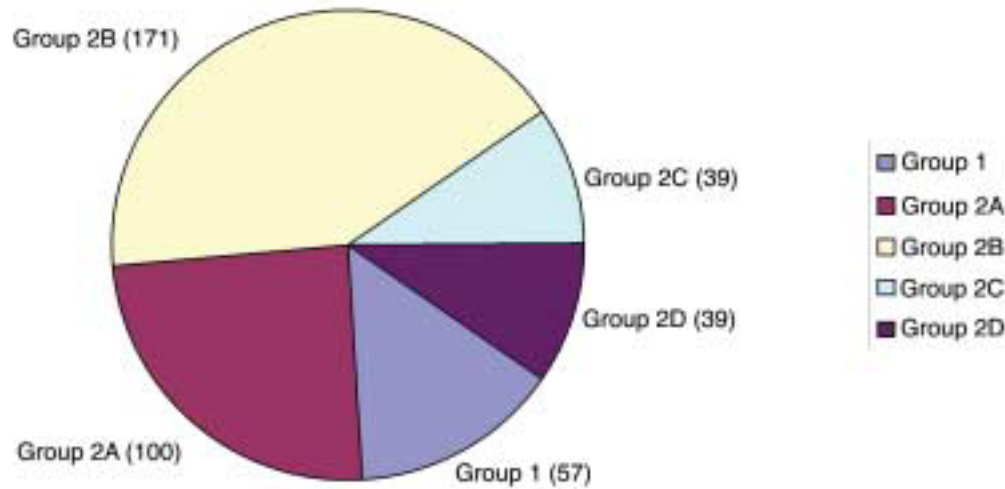
Of the 406 abdominoplasty procedures, 57 (Group 1) did not have simultaneous SAL. Three hundred forty-nine procedures (Group 2) involved simultaneous SAL, representing 86% of the total. Group 2 was further subdivided into those with less than 1000 mL aspirate (Group 2A), those with 1000 mL to 3000 mL aspirate (Group 2B), those with more than 3000 mL aspirate (Group 2C), and those with an undocumented amount of aspirate (Group 2D) (Table 1 and Figure 1).

Of note, approximately 96% of the cases involving SAL included suctioning of the abdominal area. In these cases, the lower flap was never suctioned, and overall undermining was consistent with cases involving abdominoplasty alone.

The average volume of aspirate was noted to increase progressively over the 15-year period of the study, with the average aspirate being approximately 600 mL in the first 5-year period, 1300 mL in the second 5-year period, and 1500 mL in the third 5-year period.

These groups and subgroups were compared with regard to average age, average BMI, average ASA physical status level, and average operative time to ensure consistency across groupings (Table 2). The differences between groups were statistically insignificant.

There were no major complications, including flap necrosis (open wound >5 cm), blood transfusions, deep



**Figure 1.** Relative sizes of each study group (number of patients in parentheses). Group 1, no lipoplasty; Group 2A, lipoplasty with <1000 mL aspirate; Group 2B, lipoplasty with 1000-3000 mL aspirate; Group 2C, lipoplasty with >3000 mL aspirate; Group 4, lipoplasty with undetermined amount of aspirate.

**Table 2. Comparison of patient groups**

Group	Average age	Average BMI	Average ASA*	Average surgery time (min)
Group 1	42	22	1.3	116
Group 2A	45	25	1.3	131
Group 2B	45	25	1.3	135
Group 2C	42	25	1.5	147
Group 2D	47	24	1.4	131

BMI, Body-mass index.

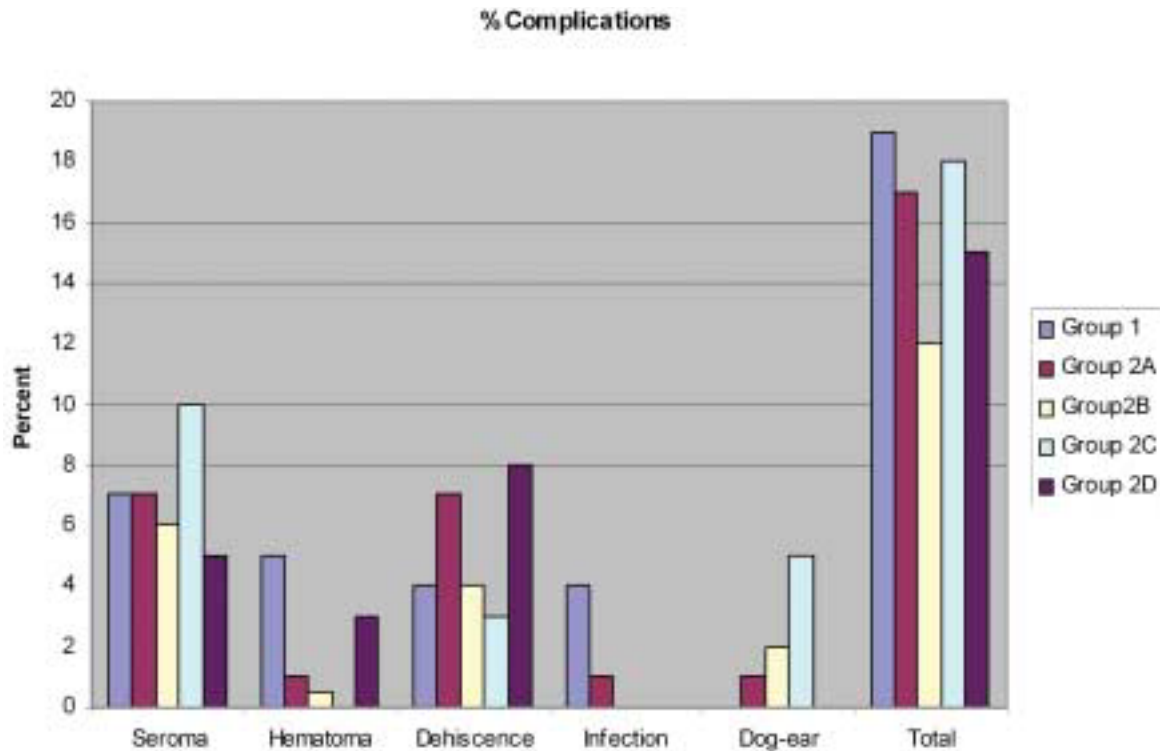
\*An ASA (American Society of Anesthesiologists) physical status level 1 patient is considered healthy, while a level 2 is considered to have mild systemic disease. Levels 3 and above represent worsening degrees of severe systemic disease.

**Table 3. Minor complications**

Group	Abdominal seroma	Abdominal hematoma	Wound (<5 cm) dehiscence	Infection	Dog-ear	Complications total cases
1	4	3	2	2	0	11/57
2A	7	1	7	1	1	17/100
2B	10	1	6	0	3	20/171
2C	4	0	1	0	2	7/39
2D	2	1	3	0	0	6/39

vein thrombosis, pulmonary embolus, myocardial infarction, or death (Table 3), and no patients required hospitalization. Minor complications are tabulated in terms of raw number (Table 3) and percent of total cases (Figure 2) for each group.

No statistically significant differences were noted between Group 1 and Group 2 (chi square analysis 0.698;  $P < .45$ , NS). Furthermore, when subdivided by volume of aspirate, no statistically significant differences were noted between subgroups: Group 1 versus 2A (chi



**Figure 2.** Incidence of minor complications in each patient group.

**Table 4.** Incidence of complications by average age and operating time

	Group 1	Group 2A	Group 2B	Group 2C	Group 2D
Average age	42	45	45	42	47
Average age with complications	40	48	45	43	53
Average operating time (min)	116	131	135	147	131
Average operating time with complications (min)	119	118	129	132	107

square analysis 0.02;  $P < .90$ , NS), Group 1 versus 2B (chi square analysis 1.5;  $P < .30$ , NS), Group 1 versus 2C (chi square analysis 0.009;  $P < .95$ , NS), Group 1 versus 2D (chi square analysis 0.31;  $P < .70$ , NS).

We compared the rate of abdominoplasty complications with regard to age and operative times (Table 4). There was no apparent correlation between complications and increased age. Similarly, the average operative times of patients in whom complications occurred were not higher. The average operative time of all cases was 2.2 hours, only 4% of cases exceeded 4 hours, and no case lasted longer than 6 hours (Figure 3).

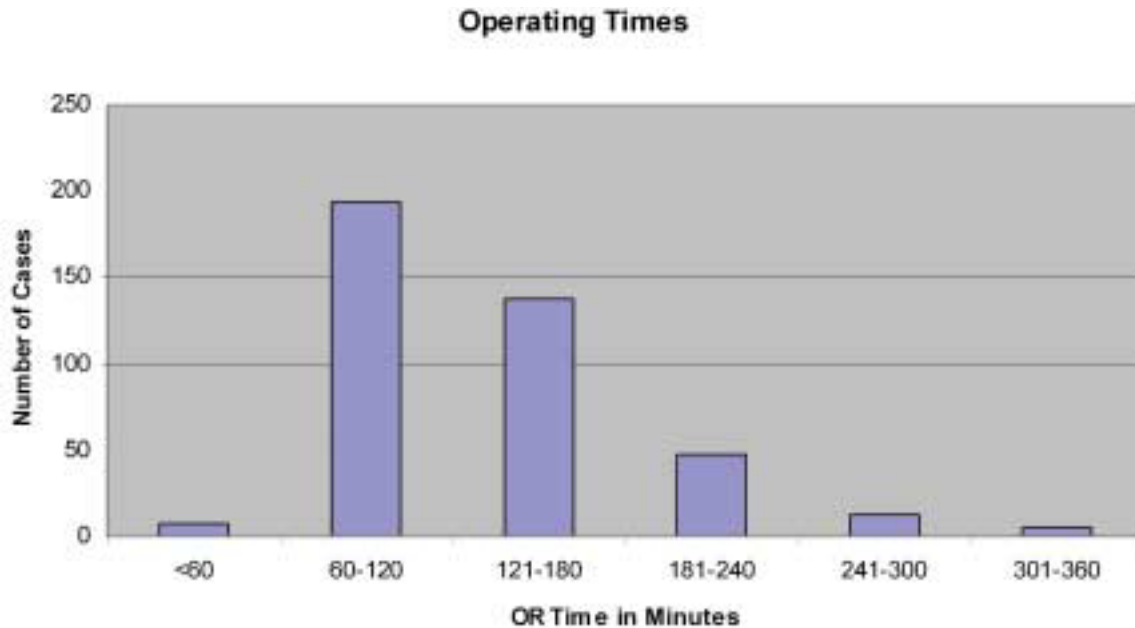
BMI's were calculated for all patients in the study, except 6 for whom the necessary data were lacking. Most patients had BMI's  $<30$ . When dividing these patients into

groups of BMI ( $<25$ , 25-29, 30-34, and  $>34$ ), no statistically significant difference existed between groups with a BMI  $<25$  versus those with a BMI  $>25$  (chi square analysis 0.65;  $P < .5$ ) (Table 5).

## Discussion

This retrospective review of 406 abdominoplasty procedures provides further evidence that combining abdominoplasty with SAL does not have a statistically significant impact on morbidity. No significant difference in complication rates was noted between the 4 groups of patients, and the overall rate of morbidity compares well with previous guidelines set by similar papers.<sup>11-13</sup>

With the growing public awareness of the benefits of aesthetic surgery, larger numbers of patients with signifi-



**Figure 3.** Duration of surgery for all procedures.

cant weight loss, and increased access to plastic surgeons, the demand for abdominoplasty will continue to rise. In many cases, SAL is necessary to maximize the aesthetic results of surgery. Few patients wish to undergo the cost, inconvenience, and potential medical consequences of multiple trips to the operating room.

Advances in surgical techniques, preoperative evaluations, and postoperative care continue to evolve, making the surgical experience both safer and more pleasant for patients. The practices of frequent transfusions,<sup>5,14</sup> multiple-day hospital stays,<sup>2,4,15</sup> and prolonged bedrest<sup>11</sup> seen in previous studies have become obsolete in the senior author's practice. Improved hemostasis with tumescent solution and electrocautery, efficient operative times, evolving pain-management strategies, and early ambulation have been keys to this success.

In its moratorium on combined abdominoplasty and lipoplasty, the Florida Board of Medicine focused on the risk of deep venous thrombosis and pulmonary embolus. As stated in the ruling:

"The Board of Medicine believes that this combination of procedures may be increasing abdominal pressure and decreasing venous return from the lower extremities in a state of hypercoagulability secondary to tissue injury, which may increase the likelihood of pulmonary emboli..."<sup>1</sup>

In the present study, meticulous care was taken to ensure that placement of lower extremity sequential com-

**Table 5. Complications in relation to BMI**

BMI	Total patients	Total complications	% complications
<25	222	23	10
25-29	124	16	13
30-34	45	7	16
>34	9	1	11

pression devices was carried out prior to induction of anesthesia. Postoperatively, all patients followed a schedule of frequent ambulation. Furthermore, operative times averaged less than 3 hours and were always limited to less than 6 hours. Using these guidelines, no documented deep venous thrombosis or pulmonary embolus occurred in this series of 406 abdominoplasty procedures.

### Conclusion

The results of this retrospective review indicate that the combination of abdominoplasty and SAL did not significantly increase the number of major or minor complications in our sequential group of 406 cases. Furthermore, no significant difference in complications was noted when comparing the various SAL volume subgroups.

Patient safety is clearly the ultimate concern with any surgery, and from this perspective, the general apprehension of medical boards, surgeons, and patients regarding

combination surgery is understandable. Reducing cost and inconvenience by combining surgical procedures could never justify a significantly increased risk of medical complications. However, as this study has demonstrated, with appropriate patient selection, meticulous perioperative care, and limited operating times, the safety of abdominoplasty with adjunctive lipoplasty appears equivalent to that of abdominoplasty alone. As a result, it seems appropriate to offer abdominoplasty combined with lipoplasty to patients, while continuing to evaluate and improve the safety and efficacy of this practice. ■

*Acknowledgments:* We thank Paul Edwards, MD, and members of the Marina Plastic Surgery Associates office and the Marina Outpatient Surgery Center for their assistance with data collection. We also thank Tyler Collins, BS, for his assistance with statistics.

## References

1. Florida Board of Medicine, Emergency Rule 64B8ER04-2: Moratorium on combined liposuction/abdominoplasty procedures in office surgery settings, 2004. Available at: <http://www.asahq.org/washington/oba-flMoratoriumNotice.pdf>. Last accessed June 16, 2005.
2. Hester TR, Baird W, Bostwick J, et al. Abdominoplasty combined with other major surgical procedures: safe or sorry? *Plast Reconstr Surg* 1989; 83:997-1004.
3. Voss SC, Sharp HC, Scott JR. Abdominoplasty combined with gynecologic surgical procedures. *Obstet Gynecol* 1986;67:181-185.
4. DeCastro CC, Daher M. Simultaneous reduction mammoplasty and abdominoplasty. *Plast Reconstr Surg* 1978;61:36-39.
5. Savage RC. Abdominoplasty combined with other surgical procedures. *Plast Reconstr Surg* 1982;70:437-443.
6. Dillerud E. Abdominoplasty combined with suction lipoplasty: a study of complications, revisions, and risk factors in 487 cases. *Ann Plast Surg* 1991;27:182-186.
7. Hughes CEH III. Reduction of lipoplasty risks and mortality: an ASAPS survey. *Aesthetic Surg J* 2001;21:120-127.
8. Stevens WG, Vath SD, Stoker DA. "Extreme" cosmetic surgery: a retrospective study of morbidity in patients undergoing combined procedures. *Aesthetic Surg J* 2004;24:4,314-317.
9. American Society of Anesthesiologists physical classification system. ASA Newsletter, Park Ridge, IL, 1963.
10. Matarasso A. Liposuction as an adjunct to a full abdominoplasty. *Plast Reconstr Surg* 1995;95:829-836.
11. Grazer FM, Goldwyn RM. Abdominoplasty assessed by survey, with emphasis on complications. *Plast Reconstr Surg* 1977;59:513-517.
12. Hensel JM, Lehman JA Jr, Tantri MP, Parker MG, Wagner DS, Topham NS. An outcomes analysis and satisfaction survey of 199 consecutive abdominoplasties. *Ann Plast Surg* 2001;46:357-363.
13. Chaouat M, Levan P, Lalanne B, Buisson T, Nicolau P, Mimoun M. Abdominal dermolipectomies: early postoperative complications and long-term unfavorable results. *Plast Reconstr Surg* 2000;106:1614-1618.
14. Pitanguy I, Ceravolo MP. Our experience with combined procedures in aesthetic plastic surgery. *Plast Reconstr Surg* 1983;71:56-65.
15. Van Uchelen JH, Werker PMN, Kon M. Complications of abdominoplasty in 86 patients. *Plast Reconstr Surg* 2001;107:1869-1873.

Accepted for publication April 7, 2005.

Reprint requests: W. Grant Stevens, MD, 4644 Lincoln Boulevard, Suite 552, Marina del Ray, CA 90292.

Copyright © 2005 by The American Society for Aesthetic Plastic Surgery, Inc. 1090-820X/\$30.00

doi:10.1016/j.asj.2005.05.003