

Aesthetic Surgery Journal

<http://aes.sagepub.com/>

One-Stage Augmentation Mastopexy: A Review of 1192 Simultaneous Breast Augmentation and Mastopexy Procedures in 615 Consecutive Patients

W. Grant Stevens, Luis H. Macias, Michelle Spring, David A. Stoker, Carlos O. Chacón and Seth A. Eberlin
Aesthetic Surgery Journal 2014 34: 723 originally published online 2 May 2014
DOI: 10.1177/1090820X14531434

The online version of this article can be found at:
<http://aes.sagepub.com/content/34/5/723>

Published by:



<http://www.sagepublications.com>

On behalf of:



[American Society for Aesthetic Plastic Surgery](http://www.asap.org)

Additional services and information for *Aesthetic Surgery Journal* can be found at:

Email Alerts: <http://aes.sagepub.com/cgi/alerts>

Subscriptions: <http://aes.sagepub.com/subscriptions>

Reprints: <http://www.sagepub.com/journalsReprints.nav>

Permissions: <http://www.sagepub.com/journalsPermissions.nav>

>> [Version of Record](#) - Jun 24, 2014

[OnlineFirst Version of Record](#) - May 2, 2014

[What is This?](#)

One-Stage Augmentation Mastopexy: A Review of 1192 Simultaneous Breast Augmentation and Mastopexy Procedures in 615 Consecutive Patients

Aesthetic Surgery Journal
2014, Vol. 34(5) 723–732
© 2014 The American Society for
Aesthetic Plastic Surgery, Inc.
Reprints and permission:
[http://www.sagepub.com/
journalsPermissions.nav](http://www.sagepub.com/journalsPermissions.nav)
DOI:10.1177/1090820X14531434
www.aestheticsurgeryjournal.com


W. Grant Stevens, MD, FACS; Luis H. Macias, MD; Michelle Spring, MD; David A. Stoker, MD, FACS; Carlos O. Chacón, MD, MBA; and Seth A. Eberlin, MD

Abstract

Background: Despite the increasing popularity of the combined augmentation mastopexy procedure among patients, the safety and efficacy of this surgery have been questioned by many surgeons.

Objective: The authors investigated the safety and efficacy of the combined augmentation mastopexy procedure.

Methods: The authors retrospectively reviewed the medical records of 615 consecutive patients who underwent combined augmentation mastopexy procedures at a single outpatient surgery center from 1992 through 2011. Patient demographics, operative and implant details, and long-term outcomes were analyzed. Rates of complications and revisions were calculated.

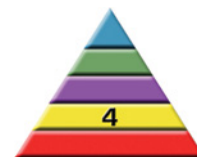Results: The most common complications were poor scarring (5.7%), wound-healing problems (2.9%), and deflation of saline implants (2.4%). Of the 615 patients evaluated, 104 (16.9%) elected to undergo revision surgery: 54 revision procedures were secondary to implant-related complications, and 50 were secondary to tissue-related complications. Our data compare favorably with previously reported revision rates for breast augmentation alone and mastopexy alone.

Conclusions: With a skilled surgeon and proper patient selection, the combined augmentation mastopexy procedure can be safe and effective.

Level of Evidence: 4

Keywords

mastopexy, breast augmentation, implants, breast lift, simultaneous augmentation mastopexy, revision surgery, secondary surgery



Accepted for publication November 6, 2013.

One-stage augmentation mastopexy was initially described over 50 years ago by Gonzalez-Ulloa¹ and Regnault,² yet appropriate documentation of revision and complication rates is still lacking. Our senior authors (W.G.S. and D.A.S.) began addressing this issue with papers published in 2006 and 2007.³⁻⁶ In recent years, the procedure has gained attention—both positive and negative—in the plastic surgery community. Critics cite the lack of literature supporting the procedure's benefits and the risks inherent in a combined operation. Supporters note that combining these procedures does not increase such risks in properly selected patients.⁷⁻¹²

Dr Stevens is a Clinical Professor of Surgery, Dr Spring is a volunteer clinical instructor, and Dr Eberlin is a resident in the Division of Plastic and Reconstructive Surgery, University of Southern California, Los Angeles. Dr Macias is a fellow, Aesthetic Surgery Fellowship, University of Southern California—Marina Plastic Surgery, Los Angeles. Dr Stoker is a plastic surgeon in private practice in Marina del Rey, California. Dr Chacón is a plastic surgeon in private practice in Encinitas, California.

Corresponding Author:

Dr W. Grant Stevens, 4644 Lincoln Blvd, Suite 552, Marina del Rey, CA 90292 USA.
E-mail: drstevens@hotmail.com

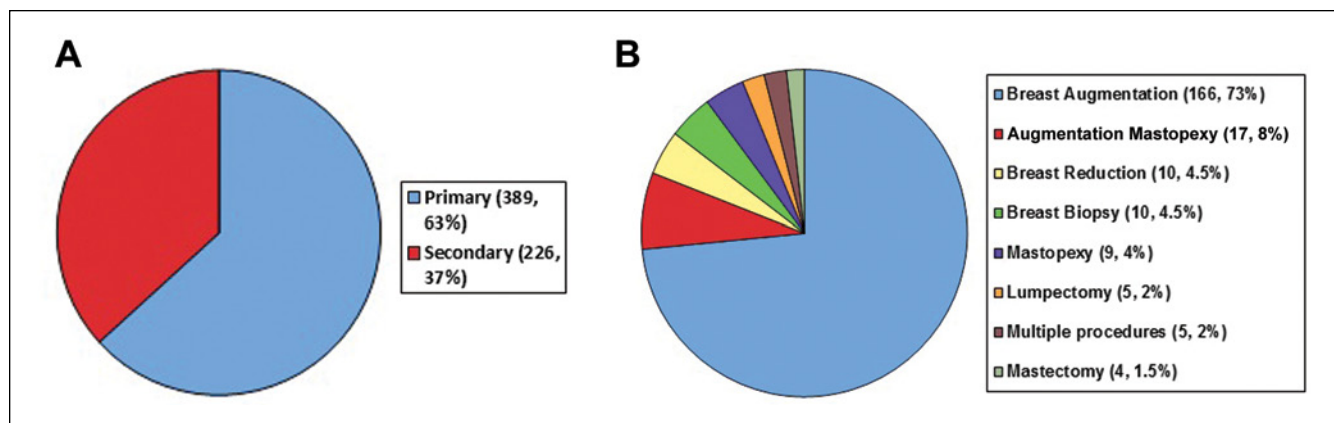


Figure 1. (A) Primary vs secondary augmentation mastopexy procedures performed from 1992 through 2011. (B) Previous breast surgeries.

We reviewed our extensive experience with 1-stage breast augmentation mastopexy and evaluated the results using specific data points, including rates of revision and long-term complications.

METHODS

The charts of 615 patients who underwent 1-stage augmentation mastopexy were retrospectively reviewed. All surgical procedures were performed at a single outpatient surgical center by 1 of 2 surgeons (W.G.S. or D.A.S.) from May 1992 through September 2011.

All patients in this study had been confirmed to be candidates for augmentation mastopexy based on grade II or higher breast ptosis and hypoplasia. Preoperative asymmetry was recorded, and the extent of breast ptosis was evaluated using the Regnault classification system.¹³ Data recorded for each patient included age, body mass index (BMI), smoking status, comorbidities, and the type of mastopexy (crescent, circumareolar, vertical, or inverted-T). Data specifically related to the implant, such as implant position (submuscular [dual plane] vs subglandular) and implant type (size, saline vs silicone gel, textured vs smooth), also were recorded, as were the duration of the surgical procedure, American Society of Anesthesiologists (ASA) level, and information on concomitant procedures (when applicable). Informed consent was obtained from the patients for our review.

Contraindications for augmentation mastopexy included patients with an ASA classification of 3 or higher, those who were emotionally unstable, and those who did not accept the possibility of revision surgery.

Preoperative and postoperative photographs were obtained for all patients. Every patient who underwent the procedure received standardized care, including perioperative antibiotics and application of lower-extremity

sequential compression devices prior to induction of general anesthesia. A consistent technique was utilized, care was taken to avoid extensive undermining of mastopexy flaps, and drains were never used. Each patient was discharged on the day of surgery, ambulated intermittently, and maintained on oral pain medication. All patients had follow-up at 1 day, 1 week, 1 month, 3 months, and 6 months, and then annually or as needed.

The following long-term follow-up data were recorded for each patient: number of revision procedures, reasons for revisions, incidence and treatment of complications, and dissatisfaction by either the patient or the surgeon. Revision and complication data were used to assess efficacy and safety. Complications were categorized further as implant related or tissue related. Implant-related complications included deflation, rupture, capsular contracture (CC), and rippling. Tissue-related complications included areolar or breast asymmetry, cosmetically poor healing, recurrent or persistent ptosis, pseudoptosis, infection, hematoma, flap loss, and loss of nipple sensation. Major flap loss was defined as skin flap necrosis of > 2 cm. Nipple loss was defined as loss or hypopigmentation of more than 10% of the areola.

The statistical significance of the data was analyzed using χ^2 analysis and the Fisher exact test; χ^2 analysis was used to compare the overall rates of revision and complication between the 1-stage augmentation mastopexy and isolated augmentation and mastopexy procedures. The Fisher exact test was used to compare the revision rates for the separate surgical technique and the various implant choices. Statistical significance was defined as $P < .05$.

RESULTS

Of the 615 patients who underwent the combined augmentation mastopexy procedure, 38 had unilateral procedures

Table 1. Implant-Related Complications

Complication	No. of Patients (%)	Type of Implant			
		Silicone		Saline	
		Textured	Smooth	Textured	Smooth
Deflation	15 (2.4)	0	0	10 (63)	5 (33)
Capsular contracture (Baker grade \geq III)	15 (2.4)	10 (67)	0	3 (20)	2 (13)
Implant palpability	4 (0.6)	1 (25)	0	2 (50)	1 (25)
Implant malposition	2 (0.3)	2 (100)	0	0	0

Data denote the number (and percentage) of patients.

and 577 had bilateral procedures (totaling 1192 breasts); 389 were primary cases, and 226 had previous breast surgery (Figure 1A). Of the patients who had previous breast surgery, 166 (73%) had undergone breast augmentation alone, and 17 (8%) had undergone combined breast augmentation mastopexy. The majority of previous procedures were cosmetic. Thirteen patients (2%) presented for reconstructive procedures. The full breakdown of the previous breast procedures is shown in Figure 1B.

The average age of our patients was 39 years (range, 17-78 years), and the average BMI was 22.7 kg/m² (range, 16-36 kg/m²). Of the 364 patients (59%) who had given birth, 291 (80%) had breastfed their infants. Forty-eight patients (7.8%) reportedly smoked before the initial consultation but agreed to stop at least 2 weeks before the procedure. Twenty-two patients (3.6%) were preoperatively diagnosed as having tuberous breast deformity, and 386 (62%) presented with breast asymmetry. The average operating time was 139 minutes, which included additional concurrent procedures in 311 patients (51%). The average follow-up time was 17.4 months (range, 1-151 months).

Silicone gel implants were placed in 487 patients, accounting for 79% of the implants placed in our study. Saline implants were placed in the remaining 128 patients (21%). The average volume of all implants (both types) was 323 cc. The majority of patients (n = 565, 92%) received textured implants, and the remaining patients (n = 50, 8%) received smooth implants. Overall, the preferred pocket was dual plane (n = 570, 93%). Forty-five patients (7%) received implants in the subglandular pocket. Four different techniques were employed for mastopexy design: inverted-T (60%), circumareolar (27%), vertical (10%), and crescent (3%). We used the laser bra technique, previously described by 1 of our senior authors (W.G.S.),⁶ for 33% of patients in the study.

There were no deaths, myocardial infarctions, pulmonary emboli, major flap loss, or nipple loss among the study population. One patient, who underwent concomitant

procedures lasting 220 minutes, had deep vein thrombosis 2 weeks after the surgery; this patient had received sequential compression devices before induction of anesthesia, as is standard protocol. She had traveled by airplane across the United States before the thrombosis was diagnosed, and she recovered fully without further incident.

Those who reported poor scarring, which was the most common complication, received either Kenalog injections (Bristol-Myers Squibb, Princeton, New Jersey) or scar revision. The most significant complication, periprosthetic infections, occurred in 5 patients (0.8%) who subsequently underwent explantation.

Saline implant deflation was noted in 15 patients (2.4% of the study group; 12.5% of patients who received saline implants). Capsular contracture was defined as Baker grade III or higher. The complete breakdown of implant-related complications is listed in Table 1.

Tissue-related complications are detailed in Table 2. Recurrent ptosis was defined as an initially acceptable outcome that bottomed out at least 6 months after surgery, whereas persistent ptosis was defined as ptosis in the early postoperative period. Wound-healing complications ranged from small suture abscesses or wound breakdowns to larger problems that were repaired in the operating room.

During the timeframe of our study, 104 patients (16.9%) underwent a revision procedure. The most common revision was the removal and replacement of implants with implants of a different size (n = 31, 5%). Implant-related complications accounted for 61 (62%) of the revisions, of which 31 were due to a desire to change the implant size. Twenty-nine patients underwent revision due to poor scarring, which accounted for the majority of tissue-related revisions. Not all of these revisions occurred in the operating room, but some of those that did were combined with a separate cosmetic procedure. The full distribution of indications for revisions is shown in Table 3.

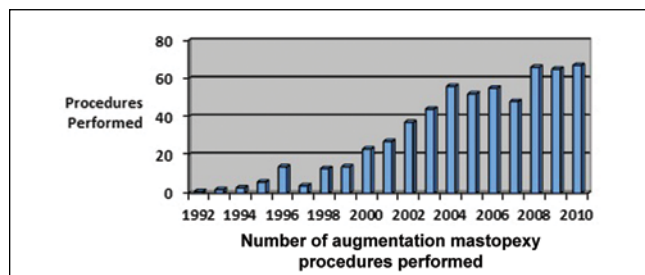
The following factors were associated with higher rates of revision: placement of saline implants ($P = .02$), the circumareolar mastopexy technique ($P = .01$), and history of

Table 2. Tissue-Related Complications

Complication	No. of Patients (%)
Poor scarring	35 (5.7)
Wound-healing problems	18 (2.9)
Areola asymmetry	12 (1.9)
Recurrent ptosis	8 (1.3)
Loss of nipple sensation	8 (1.3)
Significant infection	7 (1.1)
Breast asymmetry	7 (1.1)
Pseudoptosis	5 (0.8)
Hematoma	4 (0.6)
Partial areolar depigmentation	3 (0.5)
Persistent ptosis	3 (0.5)

Table 3. Indications for Revision

Indication	No. of Patients (%)
Desire to change implant size	31 (5.0)
Poor scarring	29 (4.7)
Implant deflation	15 (2.4)
Recurrent or persistent ptosis	7 (1.1)
Capsular contracture (Baker grade \geq III)	7 (1.1)
Breast asymmetry	6 (1.0)
Implant infection	3 (0.5)
Implant malposition	3 (0.5)
Exchange for silicone implants	2 (0.3)
Areola asymmetry	1 (0.1)
Total	104 (16.9)

**Figure 2.** Number of single-stage augmentation mastopexy procedures performed in each year of the study.

smoking ($P = .04$). Twenty revisions were directly related to the placement of saline implants (vs silicone gel implants); these included 15 implant deflations, 3 malpositioned saline

implants, and 2 direct exchanges for silicone gel implants. Although saline implants were used in only 21% of cases (128 patients), 30% of the revision cases (31 patients) involved patients with saline implants. This was found to be statistically significant ($P = .02$). The incidence of implant deflations was a large contributor to this finding. The deflation rate was not significantly higher than that of previous studies.^{14,15}

In the present study, 166 patients (27%) underwent circumareolar mastopexy. Of these, 39 patients (23.4%) underwent revision. Among the 449 patients (73%) who did not undergo circumareolar mastopexy, 65 (14.5%) underwent revision. The circumareolar mastopexy accounted for a disproportionately high number of revisions (39 of 104 patients who underwent revisions; 38%). This difference was statistically significant ($P = .01$).

Preoperatively, 48 patients (7.8% of the study population) were smokers, 13 (27%) of whom underwent revision. These patients accounted for 13% of all revisions—a statistically significant percentage ($P = .04$).

DISCUSSION

Despite being counseled that a 2-stage procedure may yield more predictable results, many patients choose 1-stage augmentation mastopexy because of its convenience and the decrease in risks vs undergoing additional surgery and anesthesia. This trend is illustrated in Figure 2.

Pitfalls of the 1-stage procedure have been documented and include technical complexities and sometimes unpredictable results.¹⁶ However, the author who reported those pitfalls later described, along with his colleagues,⁷ satisfactory results with 1-stage augmentation mastopexy. Many surgeons commonly perform this difficult and controversial procedure with acceptable aesthetic results.^{3-5,17-19}

Spear¹⁶ has noted the greater likelihood of “major disasters” with the 1-stage procedure, including nipple loss and skin flap necrosis. However, we have not encountered these serious complications. Our most common complications were poor scarring (5.7%), wound-healing issues (2.9%), implant deflation (2.6%), CC (2.4%), and areolar asymmetry (1.9%). *Wound-healing issues* is a term we applied to any case that had slower-than-expected healing or any area of wound breakdown, including minor issues such as a suture abscess that required only warm compresses. One patient had a deep vein thrombosis, necessitating hospitalization. Periprosthetic infections, which occurred in 5 patients (0.8%), required explantation. Our complication rates are comparable to those reported for either mastopexy or breast augmentation performed separately.²⁰⁻²² For the majority of procedures, we chose the dual-plane technique for implant placement. We favor this technique because the blood supply is from the musculocutaneous perforating vessels, despite the risks of motion artifact and possible lateralization of the implants. Such

Table 4. Revision Rates: Mastopexy Alone, Augmentation Alone, and Combination Procedure

Procedure	Rate of Tissue-Related Revisions	Rate of Implant-Related Revisions
Mastopexy alone ^a	8.6%	NA
Augmentation alone ^b		13% at 3 years 20% at 5 years
Combination augmentation mastopexy	7.1%	9.8%

NA, not applicable.

^aData reported previously.²¹

^bBased on results of the Mentor Saline Prospective Study (SPS).²⁰

risks are inherent in any mastopexy or breast-contouring procedure,²³⁻²⁵ and we found that the risk of these complications, or of revision, was not higher with the 1-stage operation ($P > .05$).

The main point of contention for 1-stage augmentation mastopexy is its higher rate of complications relative to the complication rates for each procedure performed separately.²⁶ To evaluate this in relation to our data, we examined findings from the Mentor Saline Prospective Study (SPS),²⁰ which is often quoted as the benchmark for evaluating complication rates after breast augmentation. For complication rates related exclusively to mastopexy, we examined our own previously reported data from 150 consecutive mastopexy patients.²¹ Because the surgeons who performed the combined augmentation mastopexy procedure were the same as those who performed the mastopexies in the present study (W.G.S. or D.A.S.), the data were not clouded by surgeon variability. This also ensured a similar patient demographic. The data showed that the combined procedure had a tissue-related revision rate of 7.1%, which is lower than the rate of 8.6% in our mastopexy review. Our implant-related revision rate for the combined procedure was 9.8%, which is less than the 13% to 20% revision rate in the SPS (Table 4). The overall trend demonstrated by the data is that the risks of the single-stage procedure are not more significant than the risks of the 2 procedures performed separately. We also compared the complication rate for our first 5 years of performing the single-stage procedure with the rate for our last 5 years, and the difference was not significant ($P > .05$). Therefore, we believe that 1-stage breast augmentation with mastopexy can be performed safely and without greater risks than 2-stage procedures, which involve repeat surgery and anesthesia.

More revisions were implant related than tissue related. The most common indication for revision was the desire to change the size of the implant (5%). Some argue that this is not a true "complication" and should not have been included in the data, but we chose to include it because proper sizing is one of the difficulties of the combined

procedure. Because the patient may have changed her mind about which size she desired, this indicates a gray area in the data. This indication was followed by the most common tissue-related reason for revision: poor scarring (4.7%). This number may be inflated because many patients who underwent scar revision also underwent other procedures simultaneously; whether they would have been interested in scar revision as an isolated procedure is not known.

Distinct trends in complication rates were observed in our study for patients who smoked before the procedure ($P = .04$), patients who received saline implants ($P = .02$), and patients who underwent circumareolar mastopexy ($P = .01$). Smoking has long been known to increase complication rates, so this finding is not surprising.²⁵ Saline implants have inherent risks that are not present with silicone gel implants. The disproportionately high number of revisions for circumareolar mastopexy may relate to periareolar scarring or to incomplete correction of ptosis. Although circumareolar mastopexy has a role in this combined procedure, it does come with increased risks.

To evaluate the efficacy of the combined procedure and indirectly evaluate patient satisfaction, we considered the revision rate for our procedure. Our overall revision rate of 16.9% compares favorably with revision rates of the Mentor SPS (13% at 3 years, 20% at 5 years)²⁰ and our mastopexy study (8.6%).²¹

It is possible that some dissatisfied patients did not return to our center to have their concerns addressed; unfortunately, this is a drawback of any retrospective study. However, in our experience, patients with postoperative concerns have been the first to return for follow-up. During the first follow-up visit, all patients were asked if they were satisfied with the size and shape of their breasts, the amount of scarring, the choice of implant, and the nipple-areola complex (NAC). Although this information was not obtained from a protocolized questionnaire, it allowed us to determine each patient's general opinion of her surgical outcomes. Based on responses to informal questioning during postoperative visits, most of our patients were very satisfied with their results. (Representative preoperative and postoperative photographs are shown in Figures 3 through 6.) However, the lack of standardized patient satisfaction surveys and follow-up was a limitation of this study. With a validated survey, we could have more accurately analyzed the satisfaction of our patients and compared it with the satisfaction of patients who have undergone staged procedures. Other considerations for assessing patient satisfaction include conducting formal surveys online, by telephone, and/or in person.

We did not perform routine screening of implanted silicone gel devices to detect silent rupture. If silent rupture occurred, it would not have been noted in this study. Silicone implant ruptures were observed intraoperatively

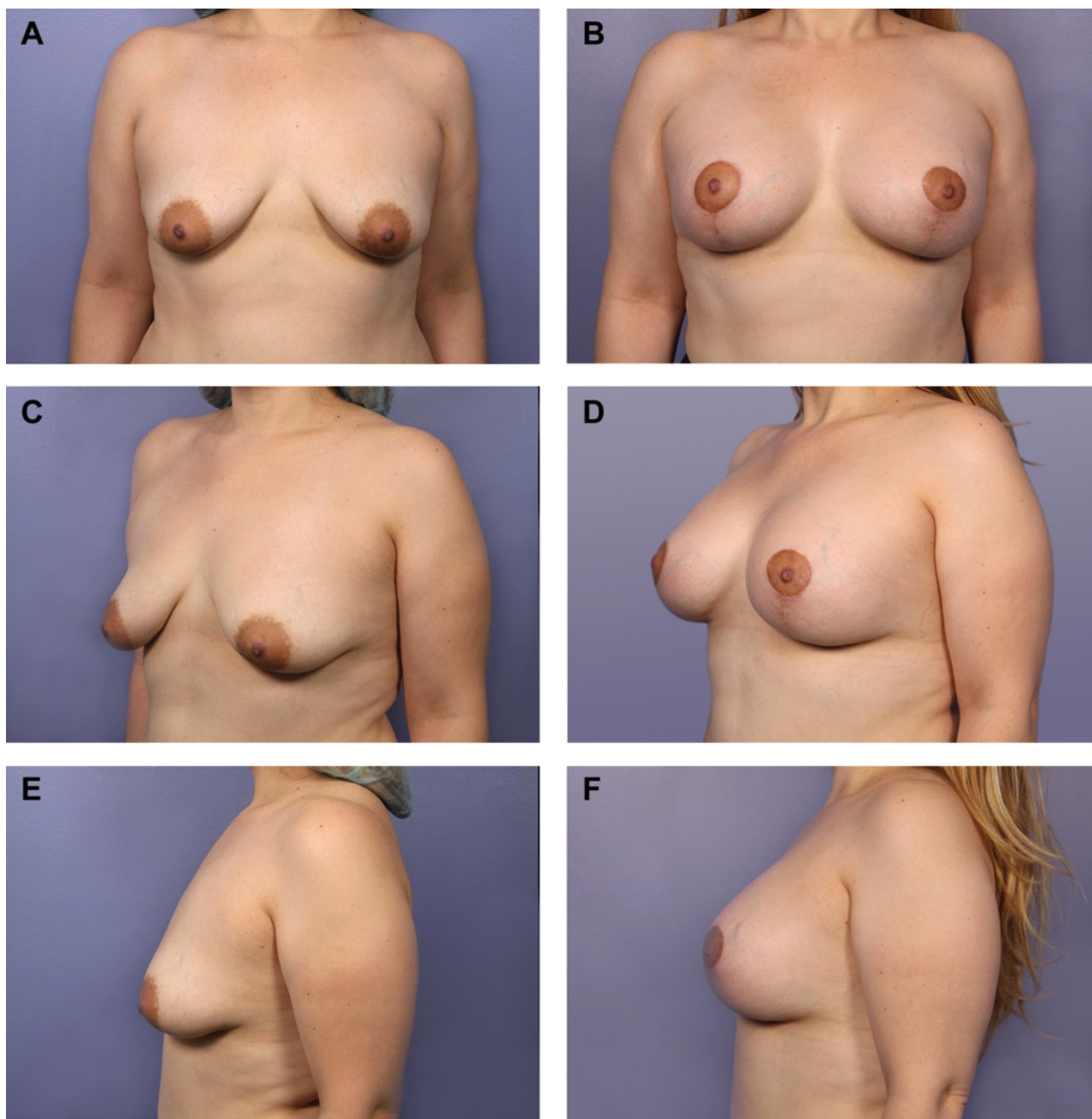


Figure 3. (A, C, E) This 30-year-old woman who presented with ptosis and hypomastia underwent circumvertical mastopexy. A small inverted-T mastopexy was performed, and 400-cc silicone gel implants (Mentor Worldwide, Santa Barbara, California) were placed in a dual plane. (B, D, F) Four months after the surgery.

in 10 patients, but none of the ruptures was a direct indication for revision. If routine screenings had occurred, it is likely that ruptures would have been the indication for at least some revisions. It is possible that recurrent ptosis was related to improper patient selection.

Circumareolar scarring may be due to the likely increase in tension caused by the implant device, in addition to the inherent tension provided by this procedure. The significance of

this increased tension—despite maneuvers such as a permanent purse-string suture to reduce tension at the dermal edge of breast skin and the NAC—is not known.

Another limitation of this study is the variation in patient pathology: a patient who undergoes an inverted-T mastopexy has a significantly different pathology than a patient selected for circumareolar mastopexy. Choosing the right procedure and tailoring it for each patient are

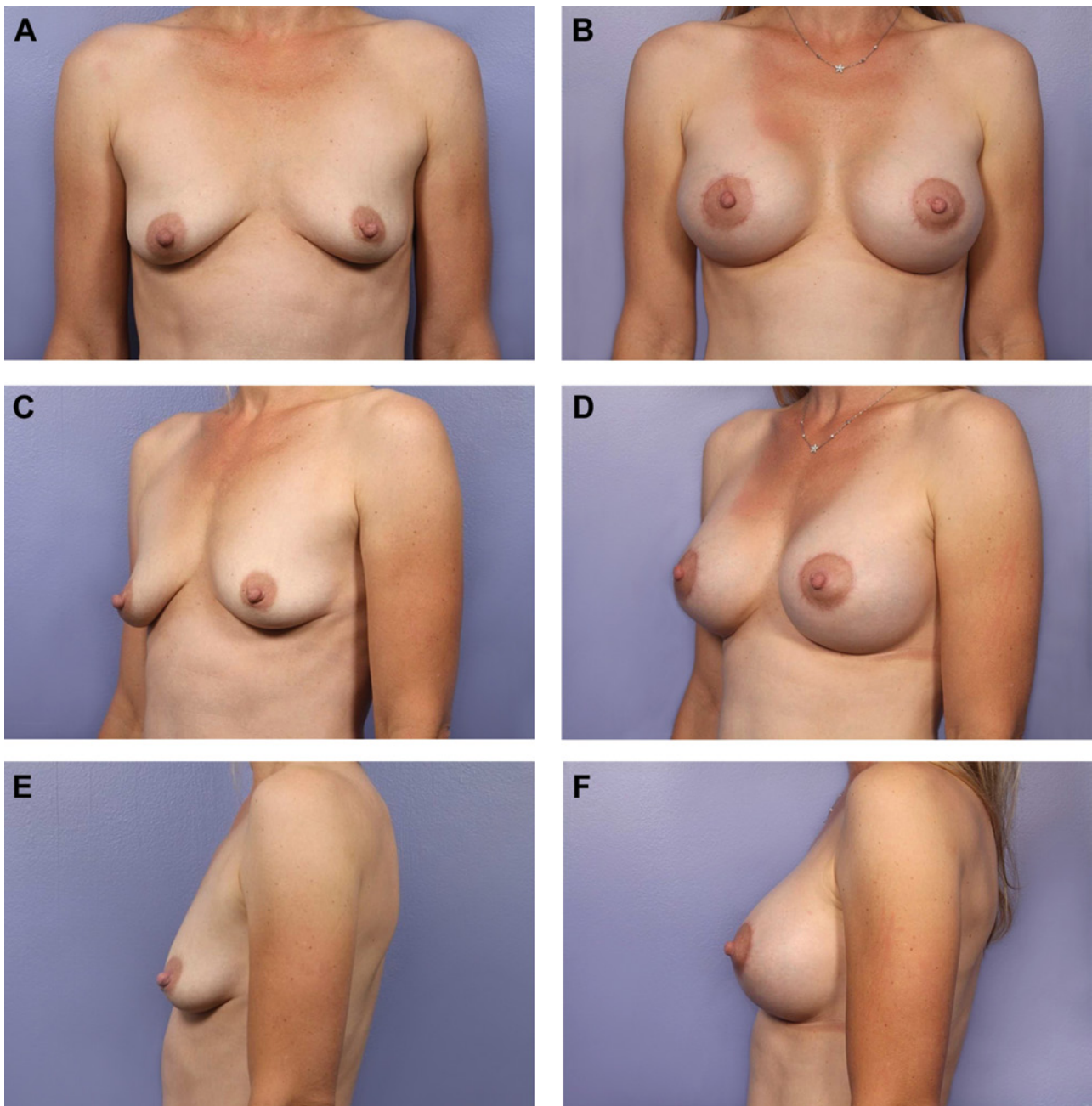


Figure 4. (A, C, E) This 37-year-old woman who presented with ptosis and hypomastia underwent circumareolar mastopexy; 330-cc silicone gel implants (Mentor Worldwide, Santa Barbara, California) were placed in a dual plane. (B, D, F) Sixteen months after the surgery.

comprehensive topics to be addressed in a future continuing medical education article in *Aesthetic Surgery Journal*.

We have seen a dramatic increase in requests for single-stage augmentation mastopexy. Patients rarely request the procedure by name, but those whose chief complaint is small sagging breasts are pleased to learn of an option that can address both issues simultaneously. However, each

case presents its own distinct set of challenges. The combined procedure decreases the breast envelope while increasing the volume of the breast; accomplishing this in 1 stage, while maintaining the 3-dimensional aesthetics of the breast, requires experience with the procedure. There is also the possibility of revision surgery being needed. Although our revision rate of 16.9% is acceptable and compares favorably with revision rates for the 2 individual

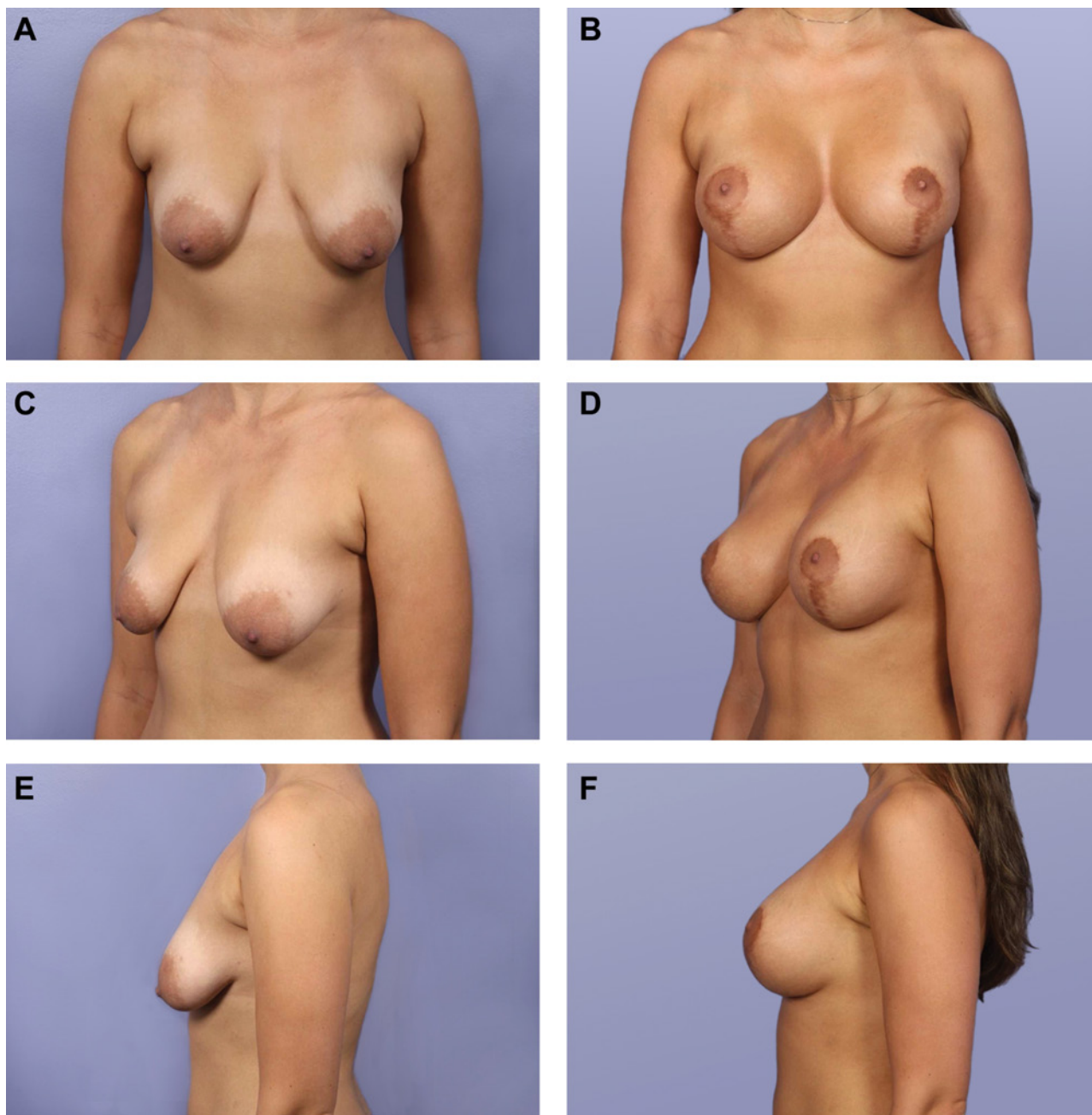


Figure 5. (A, C, E) This 24-year-old woman who presented with ptosis and hypomastia underwent circumvertical mastopexy. A small inverted-T mastopexy was performed, and a 372-cc silicone gel implant (Allergan, Irvine, California) was placed in the left breast and a 354-cc silicone gel implant in the right breast, in dual-plane fashion. (B, D, F) Ten months after the surgery.

procedures, it may be less acceptable to patients who had expected only 1 procedure. We believe that our revision rate can be decreased further by placing more silicone implants, performing fewer circumareolar mastopexies, and more strongly emphasizing the importance of smoking cessation to prospective patients, or perhaps limiting this surgery to nonsmokers.

CONCLUSIONS

Our findings indicate that 1-stage augmentation mastopexy can be performed safely and effectively by surgeons who are experienced with this procedure. Although the 1-stage operation is not without risks, the risks are not exponential (as has been suggested previously). Appropriate steps

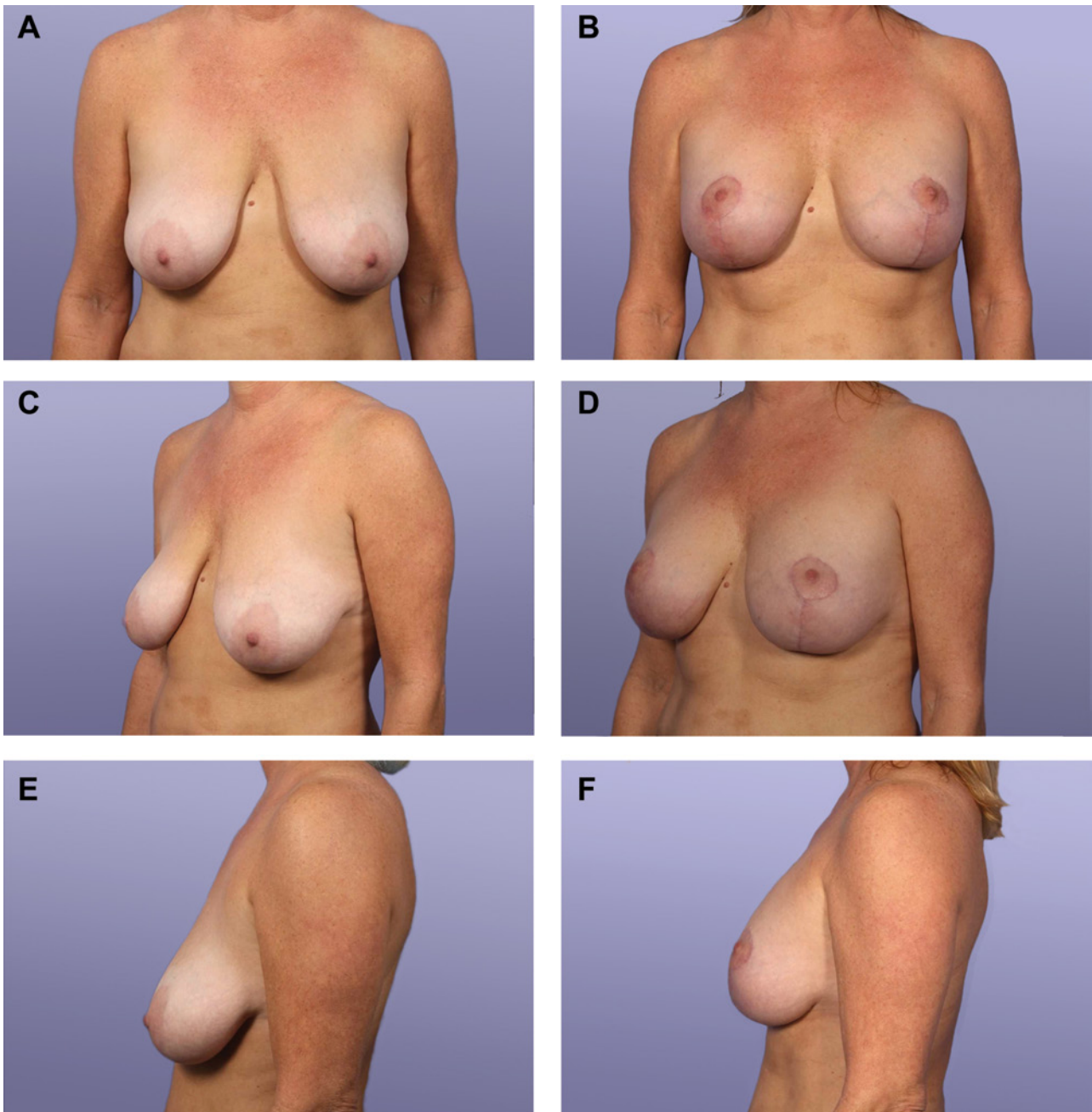


Figure 6. (A, C, E) This 52-year-old woman who presented with ptosis and hypomastia underwent circumvertical mastopexy. A small inverted-T mastopexy was performed, and a 290-cc silicone gel implant (Allergan, Irvine, California) was placed in the left breast and a 354-cc silicone gel implant (Allergan) in the right breast, in dual-plane fashion. (B, D, F) Two months after the surgery.

should be taken to minimize risks, and patients must be counseled about the possibility of revision surgery. Regardless, the 16.9% chance of requiring revision for a 1-stage procedure is significantly lower than the 100% necessity for a second operation inherent in 2-stage procedures, each of which still may require revision.

Disclosures

Dr Stevens is an investigator for Mentor CPG (Santa Barbara, CA); Cohera Medical, Inc (Pittsburgh, PA); Sientra (Santa Barbara, CA); and Silimed Cohesive Gel, Inc (Santa Barbara, CA). He is also a medical luminary for SOLTA Cutera (Brisbane, CA), Merz (Greensboro, NC), Exilis (Framingham,

MA), and Syneron-Candela (Irvine, CA, and Wayland, MA); a speaker for Allergan Academy (Irvine, CA) and Sientra; a consultant for TauTona (Menlo Park, CA); and a medical luminary and speaker for ZELTIQ (Pleasanton, CA). Dr Spring is an investigator for Cohera Medical, Inc (Pittsburgh, PA). No other disclosures were reported.

Funding

The authors received no financial support for the research, authorship, and publication of this article.

REFERENCES

- Gonzalez-Ulloa M. Correction of hypertrophy of the breast by exogenous material. *Plast Reconstr Surg.* 1960;25:15-26.
- Regnault P. The hypoplastic and ptotic breast: a combined operation with prosthetic augmentation. *Plast Reconstr Surg.* 1966;37:31-37.
- Stevens WG, Freeman ME, Stoker DA, Quardt SM, Cohen R, Hirsch EM. One-stage mastopexy with breast augmentation: a review of 321 patients. *Plast Reconstr Surg.* 2007;120:1674-1679.
- Stevens WG, Spring M, Stoker DA, et al. A review of 100 consecutive secondary augmentation/mastopexies. *Aesthetic Surg J.* 2007;27:485-492.
- Stevens WG, Stoker DA, Freeman ME, Quardt SM, Hirsch EM, Cohen R. Is one-stage breast augmentation with mastopexy safe and effective? A review of 186 primary cases. *Aesthetic Surg J.* 2006;26:674-681.
- Stevens WG, Cohen R, Schantz SA, et al. Laser-assisted breast reduction: a safe and effective alternative. A study of 367 patients. *Aesthetic Surg J.* 2006;26:432-439.
- Spear SL, Pelletiere CV, Menon N. One-stage augmentation combined with mastopexy: aesthetic results and patient satisfaction. *Aesthetic Plast Surg.* 2004;28:259-267.
- Spear SL, Low M, Ducic I. Revision augmentation mastopexy: indications, operations, and outcomes. *Ann Plast Surg.* 2003;51:540-546.
- Puckett CL, Meyer VH, Reinisch JF. Crescent mastopexy and augmentation. *Plast Reconstr Surg.* 1985;75:533-543.
- Elliott LF. Circumareolar mastopexy with augmentation. *Clin Plast Surg.* 2002;29:337-347.
- Owsley JQ Jr. Simultaneous mastopexy and augmentation for the correction of the small, ptotic breast. *Ann Plast Surg.* 1979;2:195-200.
- Karnes J, Morrison W, Salisbury M, Schaeferle M, Beckham P, Ersek RA. Simultaneous breast augmentation and lift. *Aesthetic Plast Surg.* 2000;24:148-154.
- Regnault P. Breast ptosis: definition and treatment. *Clin Plast Surg.* 1976;3:193-203.
- Stevens WG, Hirsch EM, Cohen R, Stoker DA. A comparison of 500 pre-filled saline breast implants versus 500 standard textured saline breast implants: is there a difference in deflation rates? *Plast Reconstr Surg.* 2006;117:2175-2178.
- Stevens WG, Stoker DA, Fellows DR, Hirsch EM. Acceleration of textured saline breast implant deflation rate: results and analysis of 645 implants. *Aesthetic Surg J.* 2005;25:37-39.
- Spear S. Augmentation/mastopexy: "surgeon beware." *Plast Reconstr Surg.* 2003;112:905-906.
- Caolbrace MB, Herdt DR, Cothron KJ. Simultaneous augmentation/mastopexy: a retrospective 5-year review of 332 consecutive cases. *Plast Reconstr Surg.* 2013;131:145-156.
- Tessone A, Millet E, Weissman O, et al. Evading a surgical pitfall: mastopexy—augmentation made simple. *Aesthetic Plast Surg.* 2011;35:1073-1078.
- Cannon CL III, Lindsey JT. Conservative augmentation with periareolar mastopexy reduces complications and treats a variety of breast types: a 5-year retrospective review of 100 consecutive patients. *Ann Plast Surg.* 2010;64:516-521.
- Mentor Corporation. *Saline-Filled Breast Implant Surgery: Making an Informed Decision.* Santa Barbara, CA: Mentor Corporation; 2004.
- Stevens WG, Stoker DA, Freeman ME, Quardt SM. Mastopexy revisited: a review of 150 cases for safety and efficacy. *Aesthetic Surg J.* 2007;27:150-154.
- Codner MA, Mejia JD, Locke MB, et al. A 15-year experience with primary breast augmentation. *Plast Reconstr Surg.* 2011;127:1300-1310.
- Dancey A, Nassimzadeh A, Levick P. Capsular contraction—what are the risk factors? A 14 year series of 1400 consecutive augmentations. *J Plast Reconstr Aesthetic Surg.* 2008;65:213-218.
- Pittet B, Montandon D, Pittet D. Infection in breast implants. *Lancet Infect Dis.* 2005;5:94-106.
- Hanemann MS Jr, Grotting JC. Evaluation of preoperative risk factors and complication rates in cosmetic breast surgery. *Ann Plast Surg.* 2010;64:537-540.
- Spear SL, Giese SY. Simultaneous breast augmentation and mastopexy. *Aesthetic Surg J.* 2000;20:155-165.