

Cryolipolysis and Skin Tightening

JEAN CARRUTHERS, MD, FRCSC, FRCOPHTH,* W. GRANT STEVENS, MD,†
ALASTAIR CARRUTHERS, MBBS, MRCP, FRCPC,‡ AND
SHANNON HUMPHREY, MD, FRCPC, FAAD‡

BACKGROUND Anecdotally, there have been reports of skin tightening after cryolipolysis, but this has not been studied or reported in the literature.

OBJECTIVE This clinical evaluation of patients treated with cryolipolysis in the thighs, abdomen, arms, and back assesses changes to skin texture, laxity, and cellulite at 2 study centers.

METHODS From the Vancouver site, a comprehensive review of cryolipolysis treatments was performed to assess treatment areas and retreatments. While reviewing data, investigators were struck by the noticeable skin tightening shown in clinical photographs. Subsequently, a survey of Vancouver patients was conducted to assess changes to skin texture and laxity. At the Marina del Rey site, subjects undergoing a clinical study for lateral thigh cryolipolysis were evaluated for changes to skin texture, laxity, and cellulite.

RESULTS Independent assessments by patients and investigators found consistent improvement in skin texture and laxity for treatments to the outer thighs, abdomen, arms, and back. Outer thighs also showed mild-to-moderate improvement in cellulite.

CONCLUSION This clinical evaluation demonstrates consistent improvement in skin texture, laxity, and cellulite after cryolipolysis as independently assessed by patients and investigators. Prospective clinical studies should be conducted to objectively study and quantify skin tightening after cryolipolysis.

The authors have indicated no significant interest with commercial supporters.

Cold-induced panniculitis was first described in infants over a century ago.¹ Numerous similar observations followed, but it was not until 1970, when Epstein and Oren reported the presence of a red indurated nodule followed by transient necrosis in the cheek of an infant who had been sucking on a popsicle and coined the term “popsicle panniculitis” that the differential sensitivity of fatty tissues and water-based tissues to cold was appreciated. These observations led to the realization that lipid-rich tissues are more susceptible to cold injury than the surrounding water-rich tissues.

Preclinical Studies

Cold-based treatments such as liquid nitrogen have been performed routinely in Dermatology for many

years.² However, it was not until Manstein and coworkers³ systematically studied the focal application of cooling to pig skin with subsequent significant underlying fat reduction that a new cold-based treatment was born. Subsequent porcine model studies showed a 30% reduction in fat layer thickness.⁴

Further preclinical studies showed that there was no change in serum lipid levels after the treatment and that the fat loss was due to fat cell death and subsequent scavenging by inflammatory cell activity.^{3,4}

Clinical Studies

The first human clinical studies showed that cryolipolysis was effective in reducing fat in the flanks, or

*Department of Ophthalmology, University of British Columbia, Vancouver, Canada; †Division Plastic Surgery, Keck School of Medicine, University of Southern California, Marina del Rey, California; ‡Department of Dermatology and Skin Science, University of British Columbia, Vancouver, Canada

“love handles,” and back fat.⁵ A subset of 10 of the 32 subjects in the study underwent ultrasonographic examination and showed a 22.4% average reduction in fat layer thickness.

Studies of the changes in lipid levels and liver function tests⁶ showed no abnormality. Cutaneous sensation was found to transiently decrease and return to normal by 7 weeks after treatment.⁷ Further studies have shown the safety and efficacy over multiple treatments⁸ and in darker skin types.⁹

Vancouver Experience

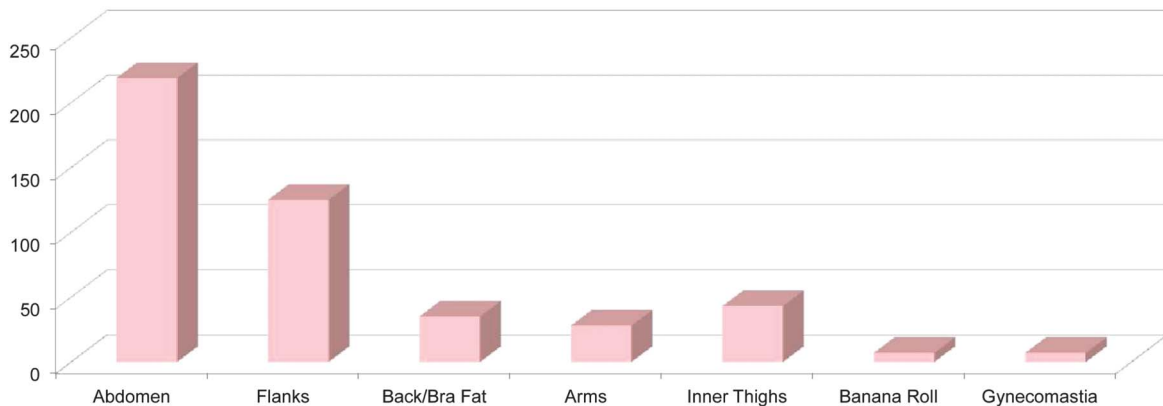
From August 16, 2010, to December 31, 2013, our group has studied 464 consecutive treatments. The majority was trunk, but 87 subjects had nontrunk treatments and retreatments (Figure 1).

The authors and their subjects noted the simultaneous tightening of skin in the areas of fat reduction. This was particularly noticeable in the abdomen and back and banana roll, but tightening and fat reduction in the upper arms and breasts was also noted.

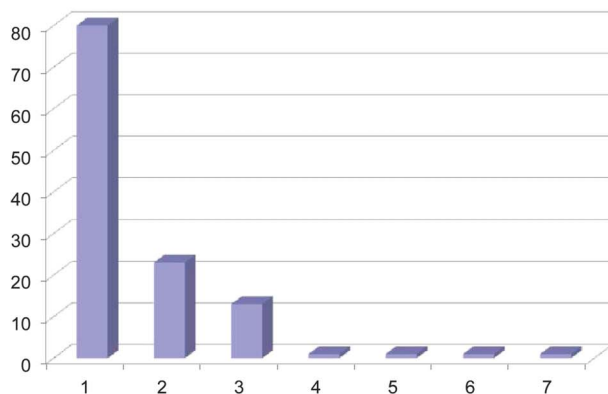
Our clinical impression of tightening with cryolipolysis was formed by studying our pre-treatment and post-treatment photographs. All our subjects are photographed before each treatment. At first, the authors were surprised that cryolipolysis would have an effect on the overlying water predominant skin and on the underlying fat. Figure 2 shows a 38-year-old female patient with visible skin tightening after significant volume reduction from cryolipolysis treatment. For photographs at both the Vancouver and Marina del Rey study sites, subjects were photographed with their feet separated at a fixed distance using a foot

RETROSPECTIVE CHART REVIEW

464 Total Treatment Areas: Trunk and Non-Trunk



Number of Re-Treatments



159 Non-Trunk Treatments and Re-Treatments in 87 Subjects

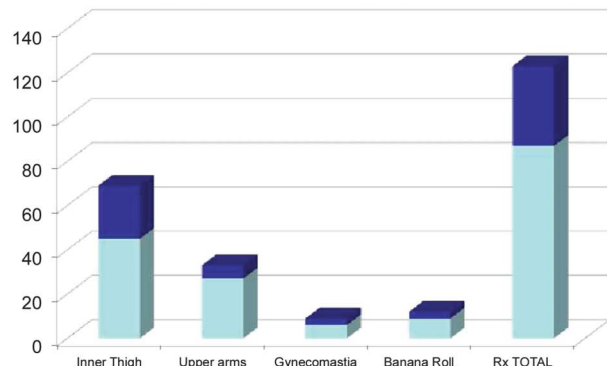


Figure 1. Summary of trunk and nontrunk treatments performed from August 2010 to December 2013.

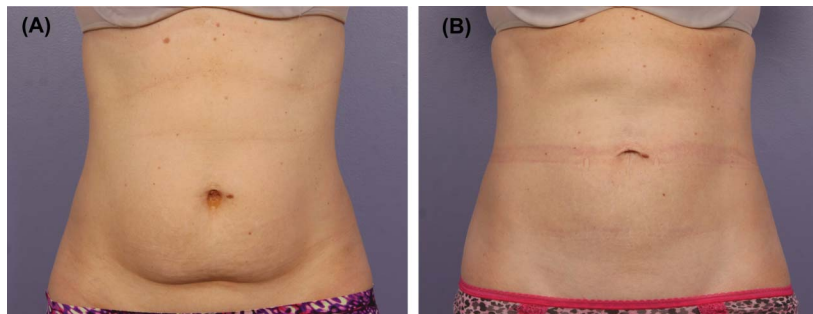


Figure 2. This 38-year-old female patient achieved visible skin tightening and volume reduction after cryolipolysis treatment. She received 2 cycles to the lower abdomen and 2 cycles to the upper abdomen. (A) Pretreatment and (B) 4 months after treatment. Procedure by W. G. Stevens.

positioning guide. At all baseline and follow-up visits, photographs were acquired using a standardized photography set-up (Nikon SLR camera, Nikon 60-mm lens, DynaLite strobes) to ensure consistency. However of all the 464 treatments, only 1 subject has requested an ancillary treatment to tighten the skin of the abdomen (monopolar radiofrequency).

In an effort to quantify the skin changes after treatment, the authors performed a clinical assessment of skin tightening in a group of patients treated with cryolipolysis in the abdomen, arms, or back. For 14 randomly selected patients, an evaluation of skin texture and laxity was performed independently by both the investigator (J.C.) and the subjects using a 0 to 3 scale, where 0 = none, 1 = mild, 2 = moderate, and 3 = significant improvement. Written surveys administered by the investigator and subjects were not presented with their before and after photographs before completing the survey.

For the Vancouver patients, mean patient age was 47.3 years (SD, 14.3 and range, 28–66 years); surveys were administered an average of 2.2 months after treatment (range, 1–4 months). The investigator and subjects found that on average, moderate-to-significant improvement was achieved for both skin texture and laxity.

In Marina del Rey, California, our colleague Stevens¹⁰ conducted a similar cryolipolysis patient chart review and heard subjective reports of skin tightening from his cryolipolysis patients. He performed a pilot study of skin tightening in his cryolipolysis clinical study population to evaluate the improvement. In all 11

subjects treated on the outer thigh using a nonvacuum conformable surface applicator at this study site,¹¹ an evaluation of skin texture, laxity, and cellulite dimpling was performed independently by both the investigator (W.G.S.) and the subjects 16 weeks after cryolipolysis treatment. They used the same scale, where 0 = none, 1 = mild, 2 = moderate, and 3 = significant improvement. For the outer thigh treatments, the investigator and subjects found mild-to-moderate improvement in skin texture, laxity, and cellulite dimpling. The mean age of the 11 patients was 43.2 years (SD, 10.7 and range, 29 to 62 years).

Both clinical assessment groups show that in each category, the subjects were more positive than the investigator, but there was a positive correlation in their analysis. For both treatment groups, there was no correlation found between patient age and improvement in skin texture, laxity, or cellulite after treatment. For cryolipolysis treatments to the outer thighs, abdomen, arms, and back, there was a consistent improvement in skin texture and laxity (Tables 1 and 2, Figure 2).

Discussion

Cutaneous neocollagenesis is a desired response to many different stimuli. With ablative treatments such as chemical peels, CO₂, and erbium laser resurfacing¹² and by nonablative treatments such as monopolar radiofrequency and high-intensity focused ultrasound,^{13,14} heat may be part of the necessary stimulus.

It has been hypothesized that skin contraction will result in response to an insult to the skin. Whether the insult is caused by heat-based therapy, chemical peels,

TABLE 1.

Subject ID	Age, yr	Treatment Area	Investigator Assessment		Subject Assessment	
			Texture	Laxity	Texture	Laxity
C.N.	31	Abdomen	1	1	1	1
J.C.	66	Abdomen	3	3	3	3
J.M.	28	Abdomen	2	2	2	2
J.T.	39	Abdomen	2	2	2	2
M.D.	31	Abdomen	1	1	2	2
M.R.	29	Abdomen	3	3	3	3
S.N.	35	Abdomen	3	3	3	3
B.C.	53	Arms	3	2	3	2
C.S.	62	Arms	3	2	3	2
G.M.	63	Arms	3	2	3	2
L.B.	52	Arms	3	3	3	3
L.E.	60	Arms	3	3	3	3
R.W.	59	Arms	3	3	3	3
D.T.	54	Back	2	2	2	2
Mean			2.50	2.29	2.57	2.36
SD			0.76	0.73	0.65	0.63

microneedling, or filler injections, subsequent wound healing and delayed skin contraction may be observed. It is believed that cryolipolysis delivers a cold-based thermal insult to the skin, which similarly results in skin tightening.

In the case of energy-based devices, heat is typically generated in the tissue, resulting in tissue restructuring and tightening or lifting.¹⁵ Whether the devices

deliver energy by ultrasound, radiofrequency, or microwave modalities, they cause heating in the targeted tissue. Heating of the dermal layer causes collagen restructuring and subsequent contraction of the collagenous scaffold, resulting in skin firming and tightening.

In use of hyaluronic acid fillers,¹⁶ stretching of the fibroblasts by the physical placement of the filler may

TABLE 2.

Subject ID	Age, yr	Treatment Area	Investigator Assessment			Subject Assessment		
			Texture	Laxity	Cellulite	Texture	Laxity	Cellulite
STE-001	40	Outer thigh	2	2	3	2	2	1
STE-002	41	Outer thigh	2	2	1	2	2	0
STE-003	54	Outer thigh	2	2	2	3	3	0
STE-004	43	Outer thigh	2	0	2	3	2	2
STE-005	33	Outer thigh	2	1	1	3	2	3
STE-006	55	Outer thigh	2	2	2	2	2	3
STE-007	29	Outer thigh	1	1	0	0	2	0
STE-008	62	Outer thigh	2	2	1	1	0	0
STE-009	31	Outer thigh	3	1	1	1	2	2
STE-010	49	Outer thigh	1	1	1	3	3	3
STE-011	38	Outer thigh	1	0	1	2	0	2
Mean			1.82	1.27	1.36	2.00	1.82	1.45
SD			0.60	0.79	0.81	1.00	0.98	1.29

be the stimulus. Aged human skin is known to have reduced fibroblast function and extracellular membrane synthesis. The authors evaluated Type I procollagen protein expression by immunohistochemistry, as it is the precursor of mature Collagen I. The staining was particularly intense around the fibroblasts adjacent to the filler, and the fibroblasts themselves were elongated as with a change in mechanical force. The staining increased 600% at 4 weeks after filler injection and remained elevated at least 12 weeks. The investigators confirmed the immunohistochemistry using ELISA. They also evaluated the gene expression for Type I and Type II collagen and found it simultaneously up-regulated.

Laser capture microscopy was used to isolate the elongated fibroblasts, so they could analyze their specific gene expression. There was a 1,200% induction of Type I procollagen gene expression, compared with an equivalent number of fibroblasts from the middle and deep dermis of vehicle-injected skin. The data show that filler provides the stimulus to the fibroblasts that make more collagen and increase the support of the extracellular matrix of the skin. They state that this is through stimulus of the transforming growth factor-beta pathway.

The production of Procollagen I was then studied by atomic force microscopy to show whether the mature collagen fibrils adjacent to the filler were organized into bundles rather than being disorganized and fragmented. The normally banded bundles extended from regions of the filler as far away as approximately 500 μm . It would seem that the new collagen formation is regional to the injected filler.

Although dermal fillers may stimulate neocollagenesis by stretching of the fibroblasts, the mechanical stretching mechanism may also be a contributing factor in cryolipolysis treatment. Except for the conformable surface applicator, most cryolipolysis treatments are delivered using vacuum applicators. The vacuum suction that pulls the tissue bulge into the treatment cup may provide mild stretching to the skin and contribute to neocollagenesis. It is worth noting, however, that the patients with lateral thigh reported

in this article from Marina del Rey were treated using a nonvacuum applicator and still noted improvements in skin texture, laxity, and cellulite.

Based on these preliminary data on skin tightening after cryolipolysis, the authors believe that prospective quantitative studies of cryolipolysis and skin tightening should be performed. A quantitative method to demonstrate changes in volume of the skin is to use the 3-dimensional Vectra system (Canfield Scientific, Fairfield, NJ). In this photographic system, the treated area is color coded. Green indicates no change, red shows increased volume, and blue demonstrates decreased volume. There has been 1 study to date looking at volumetric changes with cryolipolysis.¹⁷ In this study, 1 flank (randomized) was treated so that the partner side could serve as an internal control. The mean volume loss in the treated flank at 2 months after treatment was 56.2 ± 25.6 mL versus 16.6 ± 17.6 mL in the untreated flank ($p < .0001$). The mean absolute difference in the treated flank was 39.6 mL from a single treatment cycle. Although the Vectra system was used to image and quantify volumetric changes in the aforementioned cryolipolysis study, it is also a useful tool for the assessment of skin tightening after thermal treatment, such as laser-assisted lipolysis.¹⁸ Changes in cellulite, skin texture, and laxity are noticeable to patients and clinicians but are often difficult to discern in clinical photographs. Vectra imaging may help quantify volumetric reduction and tissue contraction after cryolipolysis.

The authors believe that the skin tightening and recontouring from cryolipolysis is superior to that of liposuction, particularly after 2 treatment cycles. In our experience, traditional liposuction rarely improves cellulite and produces minimal skin tightening. In contrast, superficial, laser-assisted, and radiofrequency-assisted liposuction techniques have yielded skin tightening, but these are invasive surgical procedures with associated complications. The skin laxity, texture, and cellulite improvement from cryolipolysis is achieved noninvasively.

This article provides a preliminary report of tissue tightening after cryolipolysis. Further objective studies should be conducted to investigate and quantify tissue

tightening. Prospective studies should be performed with baseline photographs and skin assessments to determine whether factors, such as existing laxity and patient age, might correlate with post-treatment skin tightening.

Conclusion

It would seem that neocollagenesis is associated with skin tightening and recontouring. Thus far, there is early evidence that new collagen formation may be occurring with cryolipolysis, but much more work needs to be performed to prove this stimulating proposition. Anecdotal reports from the clinicians at the Vancouver and Marina del Rey practices indicate that 25% to 30% of patients achieve noticeable improvement in skin laxity after cryolipolysis treatment.

The scientific literature contains numerous studies of skin tightening and neocollagenesis after ablative and nonablative heat-based device treatments, chemical peels, and hyaluronic filler injections, but to the best of our knowledge, this is one of the first reports of skin tightening after a cold-based therapy. Further clinical studies should be performed to quantify cryolipolysis-induced skin tightening and to elucidate the mechanism of action.

References

- Hochsinger C. Über eine akute kongelative Zllgewebsverhärtung in der Submentalregion bei ndern [in German]. *Msschr Kinderheilk* 1902;1:323–7.
- Jalian HR, Avram MM. Cryolipolysis: a historical perspective and current clinical practice. *Semin Cutan Med Surg* 2013;32:31–4.
- Manstein D, Laubach H, Watanabe K, Farinelli W, et al. Selective cryolysis: a novel method of non-invasive fat removal. *Lasers Surg Med* 2008;40:595–604.
- Zelickson B, Egbert BM, Preciado J, Allison J, et al. Cryolipolysis for noninvasive fat cell destruction: initial results from a pig model. *Dermatol Surg* 2009;35:1462–70.
- Dover J, Burns J, Coleman S, Fitzpatrick R, et al. A prospective clinical study of noninvasive cryolipolysis for subcutaneous fat layer reduction—interim report of available subject data. Presented at: Annual Meeting of the American Society for Laser Medicine and Surgery; April 28, 2009; National Harbor, MD.
- Klein KB, Zelickson B, Riopelle JG, Okamoto E, et al. Non-invasive cryolipolysis for subcutaneous fat reduction does not affect serum lipid levels or liver function tests. *Lasers Surg Med* 2009;41:785–90.
- Coleman SR, Sachdeva K, Egbert BM, Preciado J, et al. Clinical efficacy of noninvasive cryolipolysis and its effects on peripheral nerves. *Aesthetic Plast Surg* 2009;33:482–8.
- Mayoral F, Kaminer M, Kilmer S, et al. Effect of multiple cryolipolysis treatments on the abdomen. Presented at: Annual Meeting of the American Society for Laser Medicine and Surgery; April 28, 2012; Kissimmee, FL.
- Shek SY, Chan NP, Chan HH. Non-invasive cryolipolysis for body contouring in Chinese—a first commercial experience. *Lasers Surg Med* 2012;44:125–30.
- Stevens WG, Pietrzak LK, Spring MA. Broad overview of a clinical and commercial experience with CoolSculpting. *Aesthet Surg J* 2013;33:835–46.
- Stevens WG, Bachelor EP. Cryolipolysis surface applicator for non-invasive fat reduction in the outer thigh. Presented at: Annual Meeting of the American Society for Laser Medicine and Surgery; April 28, 2014; Phoenix, AZ.
- Carruthers J, Carruthers A. The effect of full-face broadband light treatments alone and in combination with bilateral crow's feet Botulinum toxin type A chemodenervation. *Dermatol Surg* 2004;30:355–66.
- Fabi SG, Massaki A, Eimpunth S, Pogoda J, et al. Evaluation of microfocused ultrasound with visualization for lifting, tightening, and wrinkle reduction of the décolletage. *J Am Acad Dermatol* 2013;69:965–71.
- Edwards AF, Massaki AB, Fabi S, Goldman M. Clinical efficacy and safety evaluation of a monopolar radiofrequency device with a new vibration handpiece for the treatment of facial skin laxity: a 10-month experience with 64 patients. *Dermatol Surg* 2013;39:104–10.
- Dobke MK, Hitchcock T, Misell L, Sasaki GH. Tissue restructuring by energy-based surgical tools. *Clin Plast Surg* 2012;39:399–408.
- Quan T, Wang F, Shao Y, Rittié L, et al. Enhancing structural support of the dermal microenvironment activates fibroblasts, endothelial cells, and keratinocytes in aged human skin in vivo. *J Invest Dermatol* 2013;133:658–67.
- Garibyan L, Sipprell WH III, Jalian HR, Sakamoto FH, et al. Three-dimensional volumetric quantification of fat loss following cryolipolysis. *Lasers Surg Med* 2014;46:75–80.
- Sasaki GH. Quantification of human abdominal tissue tightening and contraction after component treatments with 1064-nm/1320-nm laser-assisted lipolysis: clinical implications. *Aesthet Surg J* 2010;30:239–45.

Address correspondence and reprint requests to: Jean Carruthers, MD, FRCSC, FRCOphth, Jean Carruthers Cosmetic Surgery Inc., 943 West Broadway, Suite 820, Vancouver, BC V5Z4E1, Canada, or e-mail: drjean@carruthers.net